Obstructed Catheter Connection Pin Discovered During Intrathecal Baclofen Pump Exchange

Bryan S. Williams, MD, MPH and Paul J. Christo, MD, MBA

Abstract: We report a case of catheter obstruction due to complete narrowing of the lumen of a connecting pin, and catheter disconnection in a patient undergoing intrathecal Baclofen pump exchange. The patient underwent intrathecal baclofen pump implantation for treatment of lower extremity spasticity and hypertonia secondary to congenital tetraplegia. Intrathecal baclofen dose escalation occurred over the course of treatment (73 mo) from 80 to 708 mcg/d representing a 189% increase in dose. The pump had neared the manufacturer's recommended exchange interval; therefore, a pump exchange was scheduled to surgically replace the device. One week before surgery, the patient noted a distinct increase in his symptomatology and began enteral baclofen therapy. During the surgery, the pump catheter was noted to be disconnected from the pump. Upon further examination, the lumen of the connection pin positioned between the pump catheter and intrathecal catheter was completely obstructed. Postsurgically, the patient's intrathecal baclofen dose was substantially reduced from 708 to 527 mcg/d (25.6% reduction) to control hypotonicity and to reestablish an Ashworth score of 2. We discuss intrathecal baclofen therapy and a unique complication associated with a catheter connecting pin.

Key Words: intrathecal catheter, baclofen pump, catheter obstruction, spasticity, baclofen, connecting pin, spastic quadriplegia

(*Clin J Pain* 2009;25:256–259)

Spasticity after spinal cord injury (SCI) affects many patients. In fact, the reported incidence is 67% at 1 year after injury. Among these patients, 37% receive antispastic medication whereas 11% fail to respond to the treatment.[1] Initial therapy often includes maximizing oral agents and physiotherapeutic modalities. Typical therapeutic medications include botulinum toxin, dantrolene sodium, clonidine, diazepam, and baclofen.[2] Patients who fail conventional medical treatment may be candidates for intrathecal baclofen therapy (ITB). Intrathecal therapy is indicated for severe spasticity reflected by Ashworth scores of 3 to 4 or greater in the upper or lower extremities,[3] for those patients who are unresponsive to oral antispastic medications, or in patients who are experiencing intolerable adverse effects. Adverse effects of baclofen include sedation, dizziness, muscle weakness, urinary retention, and sexual dysfunction.[4,5] In particular, patients with spastic diplegia secondary to SCI or familial spastic paraparesis may benefit from intrathecal baclofen.[3]

The delivery of intrathecal baclofen may offer benefits beyond the oral preparation, and may produce adverse effects and complications related to the application of baclofen intrathecally, the surgical implantation process, or to the implantable drug delivery system (IDDS). Several complications can occur with IDDSs, which may be regarded as pharmalogic, procedural, or equipment related.

Prime benefits of ITB include its spasmolytic effects that result in improved ambulation, transfer, and hygiene. Overall, ITB patients report increased independence, mobility, and ability to perform activities of self-care.[2] Some patients enjoy a more consistent sleep pattern in the evening, and others express a renewed ability to engage in sexual intercourse.[2] Urinary function improves in certain patients as ITB eases detrusor hyperreflexia and bladder contractions.[2] Baclofen doses may be lowered when delivered intrathecally, thus limiting the adverse effects often experienced with escalating enteral therapy. This report highlights an unrecognized intrathecal catheter disconnection and connection pin occlusion in a patient with C7 spastic tetraplegia.

CASE REPORT

A 49-year-old man with a history of congenital SCI at the level of C7 and associated spastic tetraplegia was referred to the Pain Clinic for explanation of his intrathecal baclofen pump due to battery depletion. A pump exchange was scheduled to surgically replace the device with an updated SynchroMed II Infusion Pump (Medtronic, Minneapolis, MN). Eight years before the upcoming pump exchange, the patient underwent a previous intrathecal pump exchange due to catheter disconnection followed by another pump exchange to replace an inverted pump. The most recent intrathecal baclofen pump (eg, SynchroMed EL Infusion 2-piece catheter system Medtronic, Minneapolis, MN) was implanted to control intractable lower extremity spasticity and hypertonia (Fig. 1). Although the battery alarm had not been activated and the patient was experiencing no signs of baclofen underdosing or withdrawal, the pump had neared the manufacturer's recommended exchange interval (eg, 6.5 y); therefore, pump exchange was imminent.

Upon presentation to our clinic, the patient reported adequate control of his lower extremity spasticity and hypertonia (eg, Ashworth score 2 and Spasticity Index 1) with an intrathecal baclofen dose of 708 mcg/d (Novartis Lioresal Intrathecal 2000 mcg/mL) and definitely wished to continue his current therapeutic regimen. Pertinent past medical history included placement of drug eluding cardiac stents and the use of clopidogrel (Plavix) and aspirin for his coronary artery disease. Both the patient's cardiologist and primary care physician felt that clopidogrel should be maintained throughout the surgical procedure. The relative risks and benefits associated with the procedure were discussed with the patient who wished to proceed with the pump exchange.

Interestingly, 7 days before the scheduled operative day, the patient presented to his primary clinic complaining of severe spasticity and an inability to defecate. He began oral baclofen

Received for publication June 17, 2008; revised August 19, 2008; accepted August 24, 2008.
From the Department of Anesthesiology and Critical Care Medicine, Division of Pain Medicine, The Johns Hopkins University, Baltimore, MD.
No funding was received for this work.
Reprints: Paul J. Christo, MD, MBA, Department of Anesthesiology and Critical Care Medicine, Division of Pain Medicine, The Johns Hopkins University School of Medicine, 550 N. Broadway, Suite 301, Baltimore, MD 21205 (e-mail: pchrist2@jhmi.edu).

FIGURE 1. SynchroMed EL.

therapy (80 mg/d) and diazepam 10 mg/d to reduce his symptoms, though the response was minimal. It was not until the day of surgery that, the patient disclosed the onset of the aforementioned events and noted no therapeutic response from oral baclofen or diazepam.

The patient was taken to the operating room and induction of general anesthesia occurred without complication. Before incision, a fluoroscopic view of the pump revealed that the pump catheter (Fig. 2) did not seem to be attached to the intrathecal pump. An incision was made over the pump pocket scar and careful dissection exposed the pump. Under direct visualization, the pump catheter was indeed disconnected from the catheter port of the SynchroMed EL pump. That is, the strain release sleeve was completely detached from the SynchroMed EL pump catheter port (Fig. 2). The pump was removed and the intraspinal catheter and pump catheter were inspected for flow of cerebral spinal fluid (CSF). There was no appreciable free-flowing CSF, and attempts to pass sterile saline through the pump catheter were unsuccessful.

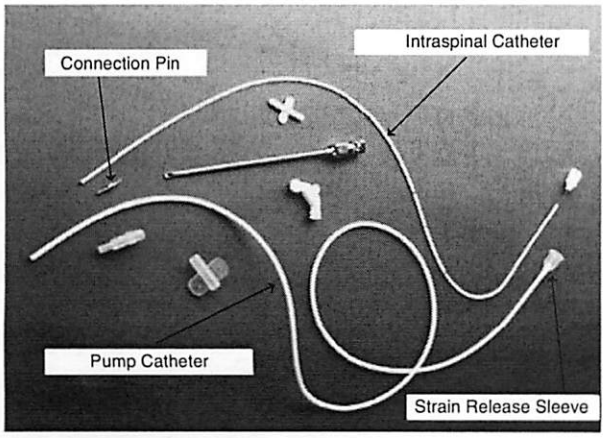

FIGURE 2. Catheters and connectors.

The connection pin suture securing the intraspinal and pump catheter was released and the pump catheter was detached from the intraspinal catheter. Flow of CSF was appreciated from the intraspinal catheter, but attempts to pass sterile saline through the pump catheter and connection pin were unsuccessful. The connection pin was removed from inside the pump catheter and sterile saline was successfully passed through the pump catheter. Upon closer inspection, the connection pin appeared to be completely occluded, thus impeding the flow of fluid through the pin's internal orifice. A new sutureless pump catheter was connected to the Medtronic SynchroMed II Infusion pump at the catheter port. The SynchroMed II Infusion pump was filled with 40 mL of baclofen (eg, Lioresal Novartis) for intrathecal administration at a concentration of 2000 mcg/mL, and his total daily dose was decreased by 20% from the preoperative dose of 708 mcg/d to avoid potential overdose by the now patent intrathecal catheter system. The pump pocket was copiously irrigated with antibiotic solution, and the new pump was placed in the pocket and sutured to the underlying fascia. The subcutaneous layer and dermal layer were closed using absorbable suture and staples.

The patient returned to the clinic 8 days after surgery with complaints of "feeling too loose" and a "lack of sensation of bladder fullness." Consequently, the basal rate of his flex dose infusion was decreased by an additional 20% during the visit. The patient presented on postoperative day 13 for staple removal and reports of continual sensory loss related to bladder fullness as well as erectile dysfunction. The intrathecal basal infusion rate was further decreased by 20%. The final daily ITB dose stabilized at 527 mcg/d at a 4-month follow-up with an Ashworth score of 1.

DISCUSSION

The first clinical use of an IDDS for neuraxial opioid delivery occurred in 1981 when clinicians implanted the device to control the chronic pain of malignancy,[6,7] however, the application of IT opioids for alleviating intractable cancer pain can be attributed to Wang et al's work in 1979.[8] Currently, IDDSs are used to treat unrelenting pain from malignant and nonmalignant pain conditions. The use of ITB for the treatment of spasticity was first reported in 1984 when 5 to 25 mcg was delivered to the intrathecal space in 2 patients with flexor/extensor spasms and hypertonia of the lower extremities due to midthoracic spinal cord injuries. ITB successfully reduced hypertonia and spasticity without producing the concomitant adverse effects typically encountered by equivalent enteral doses.[9]

Baclofen is thought to bind to $GABA_B$ receptors in the spinal cord, which inhibits the release of excitatory amino acids and subsequently leads to an antispasmodic effect. Salient benefits of ITB include targeted neuraxial drug delivery that enables a reduced drug dosage, increased efficacy, and functional enhancement in the form of greater independence and mobility.[2,3] ITB patients often report improvements in tone and spasticity, and reduced somnolence. Oral baclofen dosing may also lead to ineffective spasticity management compared with IT delivery. For instance, oral baclofen doses of 30 to 60 mg/d yield IT levels of only 12 to 96 mcg[3] due in part to baclofen's hydrophilic properties.[2] Clinically, effective ITB doses range from 100 to 400 mcg/d,[10] and typical enteral doses for spasticity range from 60 to 100 mg/d.[2] Gradual escalations in dose may be necessary if the disease process evolves, or if tolerance develops.[2] IDDS therapy with baclofen has demonstrated benefit for the treatment of spasticity, but complications can arise. Such complications may be classified as pharmacologic, procedural, or equipment-related. Studies of IDDS failures report that approximately

14% to 50% of complications relate to intrathecal catheter disruption[11–13] (equipment-related problems). More specifically, these complications may manifest as catheter dislodgement,[14] kinking, shearing, leakage, disconnection, and granuloma formation. In fact, Gooch et al[15] report disconnection of the pump catheter at the point of connection to the pump as the most frequent complication associated with IDDSs.

Catheter dislodgement and disconnection account for many IDDS-related complications[15,16] and may represent the most common cause of intrathecal drug delivery failure.[17] Moreover, restarting baclofen after dose interruptions should be performed cautiously given the risk of serious adverse effects associated with both excessive dosing (eg, somnolence, hypotonia, respiratory depression, and seizures) or underdosing (eg, hypertonicity and withdrawal seizures). This case revealed a connection pin obstruction and pump catheter disconnection during pump exchange. Upon review of the previous 73 months of ITB for this patient, an escalation of intrathecal baclofen dosing was noted after an initial daily ITB dose of 80 mcg/d and an Ashworth score of 2 (Table 1). Two years later, worsening symptomatology required an increase in baclofen dose to 210 mcg/d to maintain an Ashworth score of 2. The daily dose then reached 350 mcg/d 2 years later (ie, 4 y after implantation) to treat continual increases in spasticity and hypertonia. In the 6-month period before pump exchange, the daily dose increased from 245 to 708 mcg/d (ie, a 189% increase) to treat escalations in spasticity and hypertonia. At the time of pump exchange (ie, 6 y after the implantation) the patient received a peak ITB dose of 708 mcg/d with no additional therapeutic benefit. Typical therapeutic ITB doses range from 100 to 400 mcg/d. Dose escalation is not an uncommon process, but a substantial increase within a relatively short period of time (eg, 6 mo) associated with poor efficacy should prompt the clinician to evaluate possible medication error, programming error, pump stall, or catheter disconnection, obstruction, or dislodgement from the intrathecal space. Granuloma formation must also be considered,[18] though ITB-induced granulomas are rare.[19]

TABLE 1. Daily Intrathecal Baclofen Dose

Months Before Procedure	Daily Intrathecal Baclofen Therapy Dose (mcg/24 h)
73	80
60	80
54	132
48	210
42	255
36	275
30	330
24	350
18	350
12	378
6	245
5	615
4	678
3	687
2	708
1	708
7 d	708 + 80 mg enteral baclofen
Exchange	566
2 mo postprocedure	527
4 mo postprocedure	527

This patient had an identified catheter disconnection upon pump exchange, and did not manifest the usual symptoms of baclofen withdrawal (eg, pruritis, agitation, hallucinations, tonic/clonic movements, increased muscle spasticity, respiratory depression, obtundation, hyperthermia, and seizures)[5] at any point during the 73-month course of ITB therapy. This would indicate that the patient was receiving a portion of the daily ITB dose. However, 1 week before pump exchange, the patient presented to his treating physician complaining of severe spasticity, and an inability to defecate. On examination, the patient was noted to have an Ashworth score of 2+, increased spasms in the hip abductors and knee flexors, and clonus in the lower extremities. During this visit, the patient indicated the he had self-initiated oral baclofen (80 mg/d) 3 days earlier to help control his symptoms. If the implantation team had been aware of these changes, an intrathecal dye study would have been considered to more thoroughly evaluate the patency and integrity of the catheter.

We speculate that an untoward event (eg, patient's body habitus coupled with movement during transfer) triggered a disconnection of the pump catheter from the pump itself. This resulted in inadequate ITB delivery immediately preceding surgical pump exchange and caused the patient's new onset symptomatology. In fact, similar circumstances necessitated a previous pump exchange for catheter disconnection and pump inversion. It is also possible that persistent and progressive catheter occlusion culminated in complete catheter obstruction, overpressurization of the pump, and then catheter dislodgement. However, the fail-safe system of the pump usually does not permit overpressurization to occur according to the manufacturer.

We hypothesize that in similar mechanistic fashion to intrathecal catheter tip granuloma formation,[20] a progressive inflammatory response inside the lumen of the connection pin may have initiated lumen narrowing and propagated worsening symptoms and dose escalations in ITB therapy during the previous 6 years. Alternatively, an unrecognized manufacturing defect in the connection pin may have partially obstructed the pin's lumen, led to progressive occlusion, and then to an increase in the patient's symptoms and subsequent ITB dosing. Dosing increases during the 6 months before exchange, and the subsequent reductions in ITB dosing after pump exchange strongly suggest ITB flow interruption rather than disease progression. Furthermore, the inability to pass sterile saline through the catheter connection pin and the observed flow of CSF through the intrathecal catheter suggest flow obstruction at the connection pin.

CONCLUSIONS

ITB therapy can be a valuable method of baclofen delivery in patients who cannot tolerate oral administration; however, adverse effects and complications may arise. In this unique case report, the patient had been treated with ITB for 6 years with moderate effect, and required a significant dose escalation that far exceeded the typical clinically effective daily dose of ITB. Such dose increments should prompt clinicians to consider potential catheter-related complications (eg, dislodgment, disconnection, or kinking), possible connection pin obstruction, and manifestations of less effective ITB therapy that would prompt an investigation into potential pump/catheter failure. This

case highlights the subtlety associated with diagnosing catheter-related problems, but consistent history taking, focused examination, and accurate documentation of dose changes and responses can facilitate the process. To our knowledge, this represents the first case report of a complete IDDS catheter connection pin obstruction that lead to patient symptom exacerbation, substantial ITB dose escalations, and probable pump catheter obstruction that ultimately required pump exchange.

REFERENCES

1. Maynard FM, Karunas RS, Waring WP III. Epidemiology of spasticity following traumatic spinal cord injury. *Arch Phys Med Rehabil*. 1990;71:566–569.
2. Hsieh JC, Penn RD. Intrathecal baclofen in the treatment of adult spasticity. *Neurosurg Focus*. 2006;21:e5.
3. Belverud S, Mogilner A, Schulder M. Intrathecal pumps. *Neurotherapeutics*. 2008;5:114–122.
4. Ghafoor VL, Epshteyn M, Carlson GH, et al. Intrathecal drug therapy for long-term pain management. *Am J Health Syst Pharm*. 2007;64:2447–2461.
5. Zuckerbraun NS, Ferson SS, Albright AL, et al. Intrathecal baclofen withdrawal: emergent recognition and management. *Pediatr Emerg Care*. 2004;20:759–764.
6. Onofrio BM, Yaksh TL, Arnold PG. Continuous low-dose intrathecal morphine administration in the treatment of chronic pain of malignant origin. *Mayo Clin Proc*. 1981;56:516–520.
7. Knight KH, Brand FM, Mchaourab AS, et al. Implantable intrathecal pumps for chronic pain: highlights and updates. *Croat Med J*. 2007;48:22–34.
8. Wang JK, Nauss LA, Thomas JE. Pain relief by intrathecally applied morphine in man. *Anesthesiology*. 1979;50:149–151.
9. Penn RD, Kroin JS. Intrathecal baclofen alleviates spinal cord spasticity. *Lancet*. 1984;1:1078.
10. Grabow TS, Derdzinski D, Staats PS. Spinal drug delivery. *Curr Pain Headache Rep*. 2001;5:510–516.
11. Penn RD. Intrathecal baclofen for spasticity of spinal origin: seven years of experience. *J Neurosurg*. 1992;77:236–240.
12. Albright AL, Barron WB, Fasick MP, et al. Continuous intrathecal baclofen infusion for spasticity of cerebral origin. *JAMA*. 1993;270:2475–2477.
13. Gilmartin R, Bruce D, Storrs BB, et al. Intrathecal baclofen for management of spastic cerebral palsy: multicenter trial. *J Child Neurol*. 2000;15:71–77.
14. Tutak U, Doleys DM. Intrathecal infusion systems for treatment of chronic low back and leg pain of noncancer origin. *South Med J*. 1996;89:295–300.
15. Gooch JL, Oberg WA, Grams B, et al. Complications of intrathecal baclofen pumps in children. *Pediatr Neurosurg*. 2003;39:1–6.
16. Vender JR, Hester S, Waller JL, et al. Identification and management of intrathecal baclofen pump complications: a comparison of pediatric and adult patients. *J Neurosurg*. 2006; 104(1 suppl):9–15.
17. Dickerman RD, Stevens QE, Schneider SJ. The role of surgical placement and pump orientation in intrathecal pump system failure: a technical report. *Pediatr Neurosurg*. 2003;38:107–109.
18. Deer TR, Raso LJ, Garten TG. Inflammatory mass of an intrathecal catheter in patients receiving baclofen as a sole agent: a report of two cases and a review of the identification and treatment of the complication. *Pain Med*. 2007;8: 259–262.
19. Coffey RJ, Burchiel K. Inflammatory mass lesions associated with intrathecal drug infusion catheters: report and observations on 41 patients. *Neurosurgery*. 2002;50:78–86; discussion 86–87.
20. Murphy PM, Skouvaklis DE, Amadeo RJ, et al. Intrathecal catheter granuloma associated with isolated baclofen infusion. *Anesth Analg*. 2006;102:848–852.

