

Interventional Pain Treatments for Cancer Pain

Paul J. Christo and Danesh Mazloomdoost

*Department of Anesthesiology & Critical Care Medicine, Division of Pain Medicine,
The Johns Hopkins University School of Medicine, Baltimore, Maryland, USA*

Cancer pain is prevalent and often multifactorial. For a segment of the cancer pain population, pain control remains inadequate despite full compliance with the WHO analgesic guidelines including use of co-analgesics. The failure to obtain acceptable pain or symptom relief prompted the inclusion of a fourth step to the WHO analgesic ladder, which includes advanced interventional approaches. Interventional pain-relieving therapies can be indispensable allies in the quest for pain reduction among cancer patients suffering from refractory pain. There are a variety of techniques used by interventional pain physicians, which may be grossly divided into modalities affecting the spinal canal (e.g., intrathecal or epidural space), called *neuraxial techniques* and those that target individual nerves or nerve bundles, termed *neurolytic techniques*. An array of intrathecal medications are infused into the cerebrospinal fluid in an attempt to relieve refractory cancer pain, reduce disabling adverse effects of systemic analgesics, and promote a higher quality of life. These intrathecal medications include opioids, local anesthetics, clonidine, and ziconotide. Intrathecal and epidural infusions can serve as useful methods of delivering analgesics quickly and safely. Spinal delivery of drugs for the treatment of chronic pain by means of an implantable drug delivery system (IDDS) began in the 1980s. Both intrathecal and epidural neurolysis can be effective in managing intractable cancer-related pain. There are several sites for neurolytic blockade of the sympathetic nervous system for the treatment of cancer pain. The more common sites include the celiac plexus, superior hypogastric plexus, and ganglion impar. Today, interventional pain-relieving approaches should be considered a critical component of a multifaceted therapeutic program of cancer pain relief.

Key words: cancer; pain; analgesia; opioids; nerve blocks; epidural; intrathecal; infusion therapies; implantable drug delivery systems; intrathecal pumps; pain pumps; programmable pumps; external epidural catheter; external intrathecal catheter; neuraxial therapies; neurolytic blocks; chemical neurolysis; celiac plexus; superior hypogastric plexus; ganglion impar; ganglion of Walther; cancer pain; nonopioid therapies; malignancy; WHO 3-step analgesic ladder; palliative care

Overview

Cancer pain is prevalent and often multifactorial (Table 1). Though estimates vary, severe and chronic cancer pain occurs in approximately 33% of patients in active therapy and

in 67% of patients with advanced disease.¹⁻³ In an era of multimodal approaches to reducing pain, it is notable that 46% of dying patients lack adequate pain treatment at death, as reported by family members.⁴ Improving pain control has been a topic of interest for numerous agencies including the Joint Commission on Accreditation of Health Organizations (JCAHO), with its memoranda on Cancer Pain published in 1999⁵ and the World Health Organization (WHO) in its publication entitled *Cancer Pain Release*⁶ in 1988.

Address for correspondence: Paul J. Christo, M.D., M.B.A., Assistant Professor, Director, Multidisciplinary Pain Fellowship, Director, Pain Treatment Center, Department of Anesthesiology & Critical Care Medicine, Division of Pain Medicine, The Johns Hopkins University School of Medicine, 550 N. Broadway, Suite 301, Baltimore, MD 21205. Voice: +410-955-1818; fax: +410-502-6730. pchristo@jhmi.edu

TABLE 1. Cancer Type and Its Association with Pain

Cancer type	Patients with pain (%)
Bone	85
Oral Cavity	80
Genitourinary (Men/Women)	75–78
Breast	52
Lung	45
Gastrointestinal	40
Lymphoma	20
Leukemia	5

Source: Warfield CA, Manual of Pain Management, Philadelphia, PA: JB Lippincott Co. 1991: 145.

Reprinted with permission.

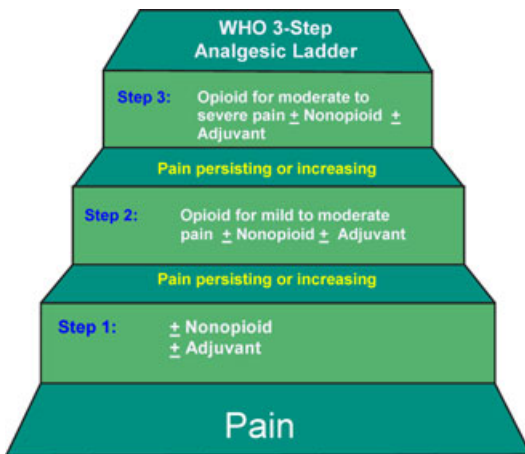


Figure 1. World Health Organization 3-Step Analgesic Ladder. Source: Management of Cancer Pain: Clinical Practice Guideline Number 9. Rockville, MD: US Dept. of Health and Human Services; 1994, AHCPR Pub No. 94-0592. Reprinted with permission.

In 1986, the WHO published a 3-tiered ladder as a guideline for managing cancer pain (Fig. 1). Prospective trials have demonstrated the ladder's widespread efficacy, and the latest trial reports 76% satisfaction with systemic medications in a 10-year follow-up of 2118 cancer patients.⁷ Yet, nearly 50% of these patients have reached the final tier of the WHO ladder in order to control their pain, and some yearn for another step of the ladder that would enhance the quality of their remaining life.

Opioid therapy remains the mainstay of cancer pain control,⁸ and adherence to the WHO analgesic ladder reportedly manages pain in the majority of cancer patients.⁹ In some patients however, the adverse-effect profile of opioids prevents them from benefiting maximally from opioid therapy and leads to needless suffering from opioid therapy and leads to needless suffering.^{4,10} For instance, gastrointestinal side effects may include both constipation and nausea. Constipation requires stool softeners and laxatives in proportion to the dosage and gastrointestinal effect of opioid use. The incidence of nausea as a result of opioid use is estimated to range from 10–40%.¹¹ Fortunately, tolerance to opioid-induced nausea usually develops over 3–5 days of continual use.¹² Patients with metastatic cancer frequently complain of fatigue as well as pain. Opioids can exacerbate fatigue, depress consciousness, and even hasten depressive symptoms. Some of these symptoms can be managed with psychostimulants like methylphenidate.¹³ Opioid-induced respiratory depression, delirium, or confusion may occur, though other causes of these conditions should be investigated in cancer patients.

For a segment of the cancer pain population, pain control remains inadequate despite full compliance with the WHO algorithm including use of co-analgesics. For example, about 14% of cancer pain patients suffer from significant unrelieved pain even when clinicians apply the WHO analgesic guidelines.¹⁴ Patients may experience side effects of medical therapy that severely attenuate the analgesic effects of the medication and reduce compliance.¹⁵ Moreover, persistent adverse effects have been reported in one of every four treatment days with WHO recommended medications.⁷ Further, pain in some patients simply fails to respond to dose escalation of opioids or co-analgesics. In these patients, opioid rotation may provide inadequate relief or may more effectively control pain at the expense of intolerable adverse effects.^{16,17}

The failure to obtain acceptable pain or symptom relief prompted the addition of a

fourth step to the WHO analgesic ladder,¹⁸ which includes advanced interventional approaches. Interventional pain-relieving therapies can be indispensable allies in the quest for pain reduction among cancer patients suffering from refractory pain. These techniques represent a welcome addition to the pain management armamentarium. The more commonly performed procedural interventions for control of cancer pain are discussed in the substance of this article. These procedural approaches include epidural and intrathecal infusion therapies; implantable drug delivery systems (IDDSs); neuraxial neurolytic interventions; and celiac plexus, superior hypogastric plexus (SHP), and ganglion impar blocks and neurolysis.

Interventional Pain-Relieving Techniques

There are a variety of techniques used by interventional pain physicians that may be grossly divided into modalities affecting the spinal canal (e.g., intrathecal or epidural space), called neuraxial techniques, and those that target individual nerves or nerve bundles, termed *neurolytic techniques*.¹⁹ Neurolytic techniques can be applied to both the neuraxial canal and to specific nerves or nerve bundles.

Neuraxial Techniques

Neuraxial techniques focus on regions of the spinal cord, that correspond to the distribution of pain. By placing medication in close proximity to the entrance of nociceptive (pain) afferent fibers, interneurons, and ascending fibers of the spinal cord, physicians are able to maximize pain relief while minimizing medication toxicity. Neuraxial drugs can bind to neuroreceptors in the dorsal horn of spinal cord, such as N-methyl-D-aspartate (NMDA), opioid, and calcium channels, that modulate the sensation of pain. Other medications lyse or rupture neuronal axons to quell

the transmission of pain until axonal regeneration. Clinicians subdivide neuraxial techniques into epidural or intrathecal approaches, depending on the anatomic site of medication delivery.

Epidural Infusion Therapy

Anatomy. The epidural space is located within the spinal canal, between the dura and connective tissues covering the vertebrae and ligamentum flavum (Fig. 2). Within the epidural space, lymphatics, arteries, and a meshwork of veins travel sporadically within a layer of loose adipose and connective tissue. No free fluid exists in the epidural space. Pain medicine specialists and anesthesiologists use this anatomic space as a repository for delivering medications that modulate pain transmission and pain perception. Epidural catheters can be inserted under sterile conditions, tunneled subcutaneously, and attached to filters. A bag containing analgesic medications is then connected to the system, which establishes the epidural infusion therapy.

Efficacy. Reducing the pain of labor or cesarean section is a common role for epidural analgesia; yet, epidurals are used to effectively treat cancer pain as well. For instance, two studies report that epidural analgesia can provide successful pain relief in 100%²⁰ and 76%²¹ of cancer patients receiving this therapy. One study reported greater pain relief from epidurals placed in the lower half of the body for low thoracic, abdominal, pelvic, or leg pain, though sufficient pain relief was also achieved in over 50% of patients with epidurals placed for upper extremity, neck, or shoulder pain.²¹ In our experience, percutaneous epidural analgesia can provide substantial relief in treating severe cancer pain, especially at the end of life.

Cost and Complications. When considering long-term epidural catheter therapy for delivery of analgesic medications, clinicians should weight the higher costs of epidural therapy beyond 3 months compared to IDDS

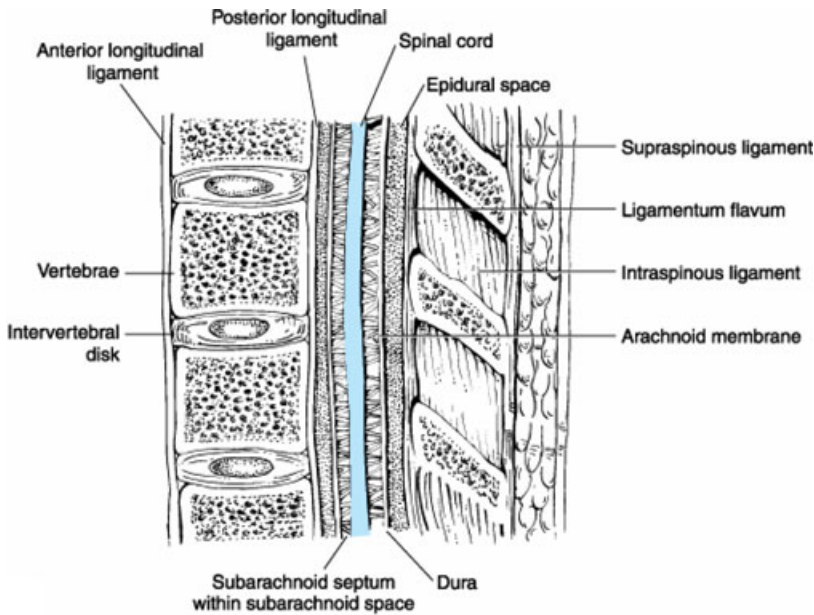


Figure 2. Anatomy of epidural space and surrounding structures (lateral view through lumbar vertebrae). Source: Morgan GE, Mikhail MS, & Murray MJ: *Clinical Anesthesiology*, 4th Edition, 1996, McGraw-Hill: <http://www.accessmedicine.com> Reprinted with permission of The McGraw-Hill Companies.

therapy²² and the risk of complications. Epidural catheter infusions require greater drug dose and volume compared to intrathecal infusions. This typically leads to increased cost and more frequent violations of the sterile catheter system to refill the medication bag and exchange the filters. Consequently, infection rates may escalate as a result of more frequent breaks in the sterile system. For instance, one study describes complications occurring in 69% of cancer patients with epidural analgesia,²⁰ and another study reports complications in 43% of patients with epidural catheter infusions.²¹ Many of these complications included catheter dysfunction, superficial and deep tissue infections, and medication-induced adverse effects, such as nausea/emesis, drowsiness, and constipation. Moreover, technical complications (such as infection and catheter dislocation and obstruction) are reported as more frequent with long-term (greater than 1 month) epidural therapy than with long-term intrathecal infusions (55% complication rate compared to 5%, respectively).²³

Compared to intrathecal opioid administration, epidural opioids may carry a reduced risk of respiratory depression. However, epidural opioids generally result in a higher rate of systemic opioid absorption (about 80–90%) and require a higher dose of administration. Furthermore, epidural catheters may lead to dural fibrosis, which can inhibit effective spread of epidural solutions, require escalating doses and volume of drugs (until the analgesia effects attenuate or the catheter obstructs), and impede drug diffusion to the intrathecal space.^{23,24}

Intrathecal Infusion Therapy

Anatomy. The intrathecal or subarachnoid space refers to the area between the spinal cord's arachnoid membrane and pia mater in which the cerebrospinal fluid circulates. Local anesthetics, opioids, and other agents can be effectively placed into this space in an effort to reduce severe cancer pain. Tunneled and externalized intrathecal catheters can be inserted under sterile conditions and used for

short- or long-term treatment of both malignant and nonmalignant pain.

External Delivery of Intrathecal Medication. Trepidation concerning heightened risks of infection and other complications has directed pain clinicians away from the application of externalized intrathecal catheters for delivering analgesic medications. However, specialists have safely used these catheters for 1–2 months and even as long as to 1.5 years²⁵ in alleviating intractable cancer and noncancer pain conditions.^{25–28} Clinical data support the safety and efficacy of externalized intrathecal analgesia for use in advanced cancer pain,^{29,30} and evidence suggests that intrathecal catheters are safer than epidural catheters if required for greater than 3 weeks of treatment.^{31,32} Furthermore, clinical studies demonstrate that intrathecal morphine can provide more satisfactory pain relief with fewer adverse effects than epidural administration of morphine.^{33–35} In contrast to epidural catheters, externalized intrathecal catheters require smaller drug dose and volume, which permits more compact, portable external infusion devices and more extended periods before refilling the device (medication bag) is necessary. Both ambulatory patients and home health refill teams often consider less frequent refills an advantage. Furthermore, home therapy with externalized intrathecal catheters may provide more acceptable analgesia and improved quality of life in advanced cancer pain than treatment with epidural catheters.³⁰

Complications. A small number of case reports demonstrate the formation of intrathecal granulomas in patients receiving continuous subarachnoid opioids or admixtures.³⁶ Most of these cases involved noncancer pain patients who were exposed to the drugs at high doses and/or over a sustained period of time. Other reports show catheter tip masses occurring in patients receiving infusions for almost 1.5 years or having exposure to morphine at high doses.^{37–39} Most externalized intrathecal infusion therapies are offered to cancer patients as a method to control their

TABLE 2. Spinal (Subarachnoid and/or Epidural) Medications

Pain Type	Medication
Visceral and somatic	<i>Opioids:</i>
	Morphine
	Hydromorphone
	Fentanyl
	Sufentanil
	Buprenorphine
	<i>Local Anesthetics:</i>
	Lidocaine
	Bupivacaine
	Tetracaine
Ropivacaine	
Neuropathic	<i>Local Anesthetics:</i>
	Lidocaine
	Bupivacaine
	Tetracaine
	Ropivacaine
	<i>N-type Calcium channel blocker:</i>
	Ziconotide
	<i>Alpha-2 agonists:</i>
	Clonidine
	Dexmedetomidine
<i>Antispasmodics:</i>	
Baclofen	

Source: Adapted from Miguel, R., Interventional treatment of cancer pain: the fourth step in the World Health Organization analgesic ladder? *Cancer Control*, 2000. 7(2): 149–56.

Reprinted with permission.

extreme pain at the end of life; therefore, granuloma formation is less likely to occur in this population. Notwithstanding the presumed lower risk of granuloma development in cancer patients, consensus recommendations for reducing risk include administering the lowest opioid dose and concentration for the longest period of time and assessing pathologic symptoms, such as diminishing pain relief and evidence of spinal cord compression.³⁶

A number of agents can be infused in the intrathecal space (Table 2), though very few are actually approved for use by the Food and Drug Administration (FDA). An IDDS represents an increasingly popular form of delivering intrathecal medications for the relief of cancer pain.

Intrathecal Medications and Implantable Drug Delivery Systems

History

Intrathecal administration of analgesic medications probably began in 1885 when J.L. Corning discovered that intrathecal cocaine produced limb paralysis in dogs, and induced anesthesia in humans.⁴⁰ The earliest application of morphine for intrathecal use was reported in 1900, and then for epidural use in cancer and postoperative pain in 1979.⁴¹ Spinal delivery of drugs for the treatment of chronic pain by means of an IDDS began in the 1980s. This form of drug delivery used a fixed, continuous rate of infusion and offered clinicians the ability to use lower doses of drug that would generally produce fewer adverse effects (such as sedation, cognitive deficits, fatigue, and constipation). By 1991, battery-powered, externally programmable IDDS pumps entered the U.S. market⁴² permitting noninvasive dose changes of drug with an external programmer. Previously, dose changes could only be made by refilling the constant flow rate pumps with different concentrations of medication.^{42,43} Today, clinicians typically implant programmable pumps when frequent dosage changes are likely. The cancer pain population reflects the broader group of chronic pain patients who often require changes to their analgesic therapies in response to the dynamic features of their pain condition.⁴³ Hence, many physicians implant programmable pumps for ease of dose changes in both cancer and chronic noncancer pain patients.

When the WHO analgesic “ladder” is applied fully, as many as 20% of cancer patients in pain fail to attain adequate pain or symptom control.^{2,14,44} This group of patients suffering from intractable pain should be considered for interventional pain-relieving therapies, including IDDSs. One randomized controlled trial (RCT) even suggests that earlier implementation of intrathecal therapy may lead to improved outcomes, such as enhanced survival.⁴⁵ Delivery of medication intrathecally usually

consists of placing a needle or small catheter into the cerebrospinal fluid where a drug can bind directly onto specific receptors in the spinal cord. Several agents, such as opioids, local anesthetics, clonidine, and ziconotide, have been infused by the intrathecal route to successfully reduce cancer pain. The intrathecal route of drug delivery holds substantial value in permitting a 300-fold reduction in opioid dose compared to the oral route.^{42,46} This dose reduction often alleviates the impact of certain toxicities associated with high-dose oral opioid therapy, such as cognitive disturbance, excessive sedation, and severe constipation. Moreover, clinical evidence suggests that intrathecal drug administration can provide more effective analgesia than systemically administered drug.⁴⁵

Intrathecal Medications

An array of intrathecal medications are infused into the cerebrospinal fluid in an attempt to relieve refractory cancer pain, reduce disabling adverse effects of oral or transdermal analgesics, and promote a higher quality of life. Morphine represents the only opioid approved by the FDA for intrathecal use. Many pain specialists and researchers consider morphine the gold standard intraspinal opioid against which all other opioids are compared. For instance, morphine has been shown to be safe and effective for long-term administration based on preclinical and human studies.⁴² In practice, hydromorphone, fentanyl, and sufentanil are used as alternatives to morphine in patients who are less responsive to morphine’s analgesic properties or who demonstrate intolerable adverse effects to morphine. In fact, guidelines from the 2004 Polyanalgesic Consensus Conference (an expert group that updates clinical guidelines for the use of intraspinal drug infusion in pain management) recommends hydromorphone along with morphine as a first line agent for consideration among pain practitioners.⁴⁷

Clonidine, an alpha-2 agonist with analgesic efficacy, is FDA approved for epidural use in

the management of cancer pain. A large, well-designed study performed by Eisenach and colleagues reported the beneficial effects of epidural clonidine for the management of severe cancer pain with neuropathic features.⁴⁸ Further, Coombs and colleagues reported the effectiveness of intrathecal clonidine in combination with hydromorphone for the treatment of intractable cancer pain.⁴⁹ Clonidine's role as a monotherapy is often dwarfed by its more common use as a dual intrathecal agent with morphine or hydromorphone. Clinically, clonidine seems to simultaneously enhance analgesia and reduce opioid-related toxicity. Practitioners also consider clonidine a useful agent in concert with local anesthetics. Used alone or in combination with opioids or local anesthetics, clonidine can be beneficial in treating patients who exhibit a neuropathic component to their pain.⁵⁰

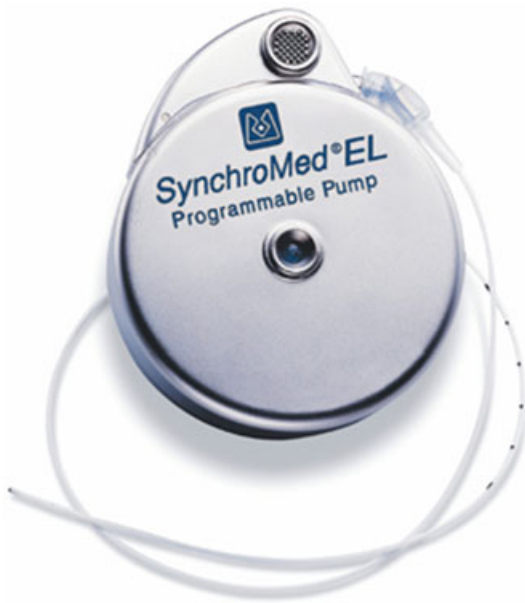When pain becomes refractory to singular treatment with intrathecal opioids, it may respond to the addition of local anesthetic. Though bupivacaine is not approved by the FDA for intrathecal use, substantial clinical experience and several reports in the literature support its application for treating cancer pain. Moreover, both the Polyanalgesic Consensus Conference⁴⁷ and the Cancer Pain Best Practices Algorithm⁵¹ recommend intrathecal bupivacaine as either a first- or second-line agent for the control of refractory cancer pain. Most clinical reports of intrathecal bupivacaine describe combination therapy with morphine, though hydromorphone or other opioids can be substituted for morphine. Bupivacaine used in concert with morphine can behave synergistically to reduce severe cancer pain and attenuate opioid-related toxicity. For instance, the addition of intrathecal bupivacaine to morphine permits a lowered dose of morphine while potentiating treatment efficacy in patients with refractory cancer pain.^{26,52} Clinical experience with bupivacaine demonstrates its effectiveness for controlling neuropathic pain or mixed neuropathic and nociceptive pain associated with malignancy.^{26,47,51} This parallels the applica-

tion of intrathecal clonidine to both neuropathic and mixed cancer pain conditions.

Intrathecal ziconotide is approved by the FDA for the treatment of refractory cancer pain or AIDS, and data demonstrate its analgesic capability.⁵³ Moreover, some patients with opioid-resistant pain or with intolerable opioid adverse effects may experience relief with ziconotide.⁵³ The most recent guidelines from the Polyanalgesic Consensus Conference (2007) place ziconotide on a par with morphine and hydromorphone as a first-line agent for the management of pain.⁵⁴ Given its blockade of the N-type voltage-sensitive calcium channels in the spinal cord,⁵⁵ ziconotide does not induce a withdrawal syndrome upon discontinuation.⁵⁶ However, significant cognitive impairment and psychiatric changes can be associated with dose escalation; therefore, clinicians should increase this drug slowly and carefully in order to avoid these drug-limiting effects. Due to its adverse effect profile, ziconotide has yet to gain wide acceptance as an effective analgesic agent for managing cancer pain.

IDDS Overview

An IDDS consists of a small, hockey puck-sized electronic pump that delivers drug(s) to the intrathecal space through a catheter (Fig. 3). Physicians implant the pump subcutaneously in the anterior wall of the abdomen and tunnel the catheter across the flank to the intrathecal space. A reservoir containing the drug is refilled through a port, which is accessed by a needle inserted through the skin. Practitioners program the pump (for instance increase or decrease the dose) by an external, hand-held device, which controls the rate of infusion, delivers bolus doses, and provides information about the pump's functional status. The battery life of state-of-the-art programmable pumps can reach 7 years. Consequently, most cancer patients with advanced disease will not require surgical pump replacement during their average lifetime. Advantages of IDDS over tunneled, externalized intrathecal or epidural catheters used for pain control include patient



© Copyright Medtronic, Inc.

Figure 3. Implantable drug delivery system (IDDS).

mobility, ease of use, lower maintenance, and cost-effectiveness.²² Potential complications of an IDDS reported in studies include pump malposition, wound infection, nausea/emesis, pruritus, urinary retention, and hardware malfunction.⁵⁷

Cost Effectiveness

Compared to medical management or to an exteriorized epidural catheter for treating chronic pain, IDDS has been shown to offer cost savings over time.^{22,58} For instance, de Lissovoy and associates studied the cost effectiveness of IDDSs infusing morphine for failed back surgery syndrome. The research group compared intrathecal morphine therapy to medical management and determined that IDDS therapy was cost effective for patients when the duration of therapy exceeded 12–22 months.⁵⁸ Furthermore, in comparing IDDSs to epidural morphine delivery with an external pump, Bedder and colleagues showed that the costs of therapy are equivalent at 3 months (the break-even point), despite the

higher upfront costs associated with intrathecal pump implantation. At 1 year, the costs of epidural morphine treatment were twice those of IDDS therapy.²²

Selection Criteria

No uniform protocol exists for selecting patients with malignant pain for intrathecal therapy. Generally, pain specialists consider patients for IDDSs if they suffer from chronic, intractable cancer pain, report insufficient pain relief or intolerable adverse effects from systemic agents, respond favorably to a screening trial, and have a life expectancy of at least 3 months.^{42,45} Both the patient and pain specialist should carefully assess the decision to proceed with long-term intrathecal therapy because the device requires ongoing management and responsible care.

Trialing Protocol

Techniques for trialing intrathecal agents range from a single injection of drug to continuous infusion of medication with a catheter. There is no consensus that a particular screening protocol leads to a more successful outcome, so techniques vary according to physician preference. All clinicians should assess patients during the trial and include elements of pain, function, mood, and adverse effects.^{42,59} Many practitioners interpret a 50% decrement in pain along with a favorable side-effect profile as predictive of sustained success with an IDDS⁶⁰; however, no studies provide outcome-based data that support the type or level of improvement necessary for successful IDDS treatment. Regular monitoring of pain relief, functional status, and medication-related adverse effects should be initiated once chronic intrathecal therapy has begun. Physicians and patients must also consider the logistics of ongoing pump maintenance, including refills of drug and dose changes. For example, both unplanned interruptions in therapy that may cause withdrawal symptoms and improper dose escalations can pose serious health risks to a medically vulnerable population of patients.

Oncologists typically refer patients for intrathecal therapy when patients with cancer pain fail comprehensive medical management or experience unacceptable adverse effects from conventional delivery (oral, parenteral, or transdermal) of analgesic medications. A growing number of physicians now refer such patients for intrathecal therapy when the oral route of drug delivery is unreliable. For instance, patients with substantial pain who may be undergoing an aggressive chemotherapeutic regimen may be ideal candidates for the intrathecal approach.

Efficacy of IDDS

Several cohort studies have demonstrated the efficacy of IDDSs for alleviating intractable cancer pain since their inception in 1991.^{34,61–66} Stronger evidence for effectiveness derives from a multicenter, RCT of over 200 refractory cancer pain patients. In this study, Smith and co-workers compared IDDS therapy (opioid +/- bupivacaine) plus medical management (opioids +/- adjuvants) to medical management alone.⁴⁵ At 4 weeks, the IDDS plus medical management group reported greater reduction in pain and drug-related toxicity, a significant decrease in fatigue, and an elevated level of consciousness. Further, 60% of IDDS patients compared to 42% of medical management patients reported a visual analog scale score of less than 4, which represents mild pain-interference and improved function.⁶⁷ Even more striking was the finding of improved survival at 6 months among IDDS patients—54% of IDDS patients alive at 6 months versus 37% of patients alive in the medical management alone group. IDDS therapy may have contributed to longevity by allowing patients to enhance their level of activity, reduce the risk of pulmonary embolism, improve their nutrition, and develop a greater “will to live.”⁶⁸

Chemical Neurolysis

In general, neurolysis describes intentional injury to a nerve or group of nerves by chemi-

cal (e.g., alcohol or phenol), thermal (heat), surgical, or cryogenic (freezing) methods with the intent to relieve pain. The effects of neurolytic therapy typically persist between 3–6 months, although the response can vary widely. Many pain specialists apply neurolytic techniques to discrete clinical conditions in which patients suffer from refractory cancer pain and have otherwise failed previous analgesic and complementary approaches. Neurolysis is less commonly invoked for nonmalignant pain due to its risks of neuritis, neurologic deficit, damage to non-neural tissue (such as skin or organs) or nontargeted neural structures, and permanent effects. Additionally, the therapy can render incomplete pain relief due to existing adhesions, tumor burden, or nerve regeneration. Nonetheless, neurolysis can provide effective analgesia and life-enhancing benefits when applied appropriately. For instance, alcohol neurolysis for irreversible abdominal pain from pancreatic cancer can provide significant analgesia for up to 6 months and improve survival ($P < 0.0001$).⁶⁹ There are several sites for neurolytic blockade of the sympathetic nervous system for the treatment of cancer pain (Table 3; Fig. 4). Sympathetically mediated pain associated with gastrointestinal and genitourinary cancers tends to respond to celiac plexus, SHP, or ganglion impar neurolytic blocks.

Neurolytic techniques more effectively treat discrete, well-circumscribed pain that patients can identify easily (such as hemithoracic pain from malignancy). Interestingly, visceral pain—often diffuse and vague generally—responds to neurolysis despite its broadly based clinical features. For instance, celiac plexus or splanchnic neurolysis is often considered in patients with abdominal and referred back pain secondary to visceral or retroperitoneal malignancy in the abdomen, and SHP neurolysis can effectively reduce pelvic pain due to visceral pelvic cancers. Empirical data suggest that visceral and somatic pain respond more favorably to neurolytic therapy than does neuropathic pain.

TABLE 3. Neurolytic Blocks

Nervous system location	Corresponding anatomic structures
Stellate ganglion	Head, meninges, arm, eye, ear, tongue, neck, larynx, pharynx
Gasserian ganglion	Face/mouth, typically associated with trigeminal neuralgia
Thoracic sympathetic chain	Upper—head, arms Middle—thorax: heart, lung, esophagus, bronchi, pleura, trachea, pericardium Lower—bladder; abdominal organs, uterus
Celiac plexus (splanchnic nerves)	Pancreas, abdominal vessels, esophagus to transverse colon, liver, adrenals, ureters
Lumbar sympathetic chain	Lower extremity vessels and skin, ureters, kidney, testes
Hypogastric plexus	Uterus, ovaries, vagina, bladder, prostate, testes, descending and sigmoid colon, seminal vesicles
Sacrococcygeal ganglion (ganglion impar or ganglion of Walther)	Perineum, rectum, anus, vagina, distal urethra, vulva

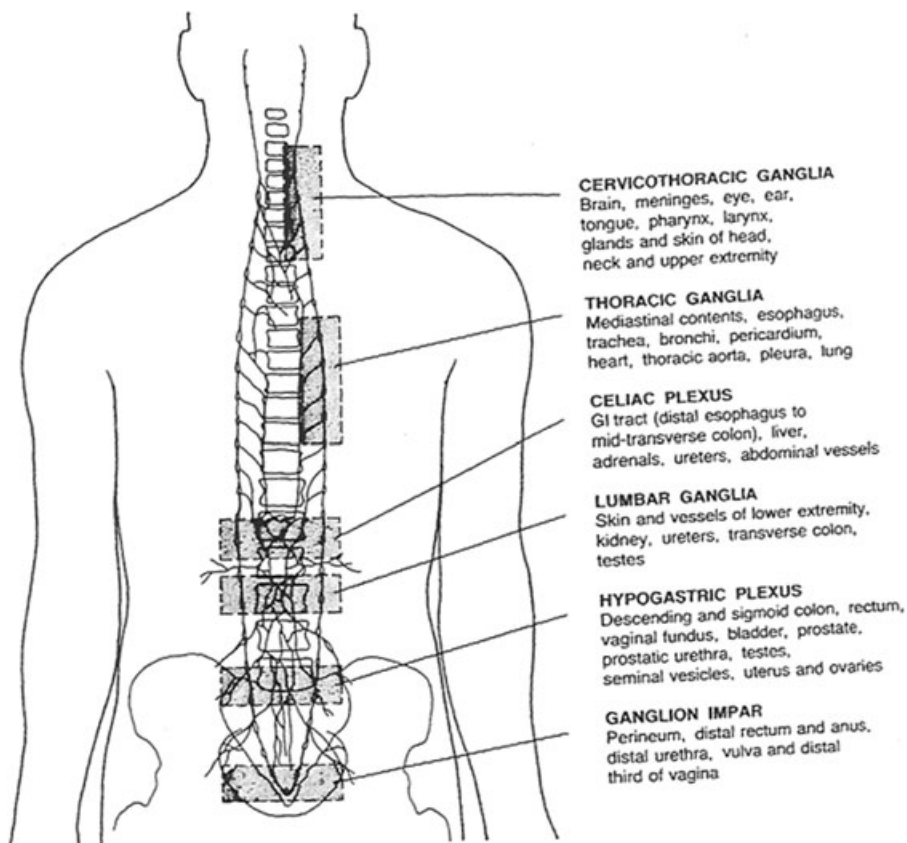


Figure 4. Sites for neurolytic blockade of the sympathetic nervous system and relevant structures. *Source:* Plancarte R, Amescua C, & Patt RB: Sympathetic neurolytic blockade. In Patt RB (ed): *Cancer Pain*. Philadelphia: JB Lippincott, 1993, pp 377–425. *Reprinted with Permission of Lippincott Williams & Wilkins.*

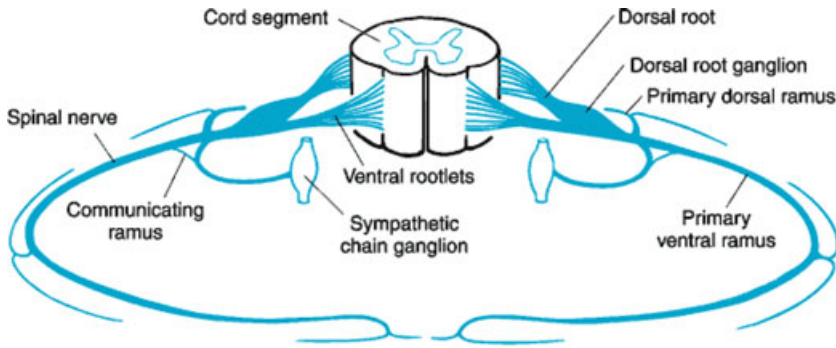


Figure 5. Division of sensory and motor fibers in the spinal cord. *Source:* Waxman SG: *Clinical Neuroanatomy*, 25th edition, McGraw-Hill: <http://www.accessmedicine.com> Reprinted with permission of The McGraw-Hill Companies.

Neurolytic agents predominantly affect neuronal axons, not cell bodies; therefore, pain relief is temporary secondary to axonal regeneration and neural plasticity.⁷⁰ For chemical neurolysis, clinicians generally use phenol, absolute alcohol, or glycerin. Chemical neurolysis is preferred over other modalities for procedures that must disrupt diffuse neural networks, such as the SHP and the celiac plexus.

Pain physicians typically use alcohol or phenol when lysing neural structures for analgesic purposes. For instance, alcohol was first used as a neurolytic agent in 1902 in order to treat trigeminal neuralgia.⁷¹ This agent is quite noxious and can induce a burning sensation in the region to which it is targeted. Therefore, pretreatment with a local anesthetic should be strongly considered. Phenol was first introduced in the 1950s and gained widespread popularity, in part because of its analgesic as well as neurolytic properties.⁷¹

Neuraxial Neurolytic Blocks

Neuraxial neurolysis dates back to 1931 when Dogliotti described the use of subarachnoid alcohol for the treatment of sciatic pain.⁷⁰ Since that time, neuraxial chemical neurolysis via the intrathecal or epidural approach is only considered in advanced, irreversible, and progressive illness (such as cancer) due to the severity of potential complications. Careful patient

selection and technique are therefore critical. For instance, the pain should be well localized in a patient with a short life expectancy.⁷² Intrathecal neurolysis is strongly considered in patients with terminal cancer pain, pain that is unresponsive to typical analgesic modalities, patients with unilateral pain that is localized to adjacent dermatomes in the trunk, thorax, or abdomen, and pain that is located away from the innervation of the extremities and sphincters.⁷² More successful outcomes with one particular intrathecal neurolytic agent have not been confirmed, though many pain specialists believe that alcohol produces better analgesia with longer duration than phenol. Patients undergoing neurolytic therapy realize that the block will gradually lose effectiveness over time and may need to be repeated. Furthermore, their malignancy may progress and cause pain in other regions of the body.

Anatomy and Function. Neuraxial neurolysis is intended to selectively interrupt sensory transmission while sparing motor function in the affected area (Fig. 5). This is possible due to the division between sensory and motor fibers of the spinal cord: the dorsal root carries sensory fibers and the ventral root carries motor and sympathetic fibers.⁷³ Hence, neurolysis is designed to block nociceptive input from injured tissues at the spinal and epidural level. This is accomplished by selectively injuring the dorsal

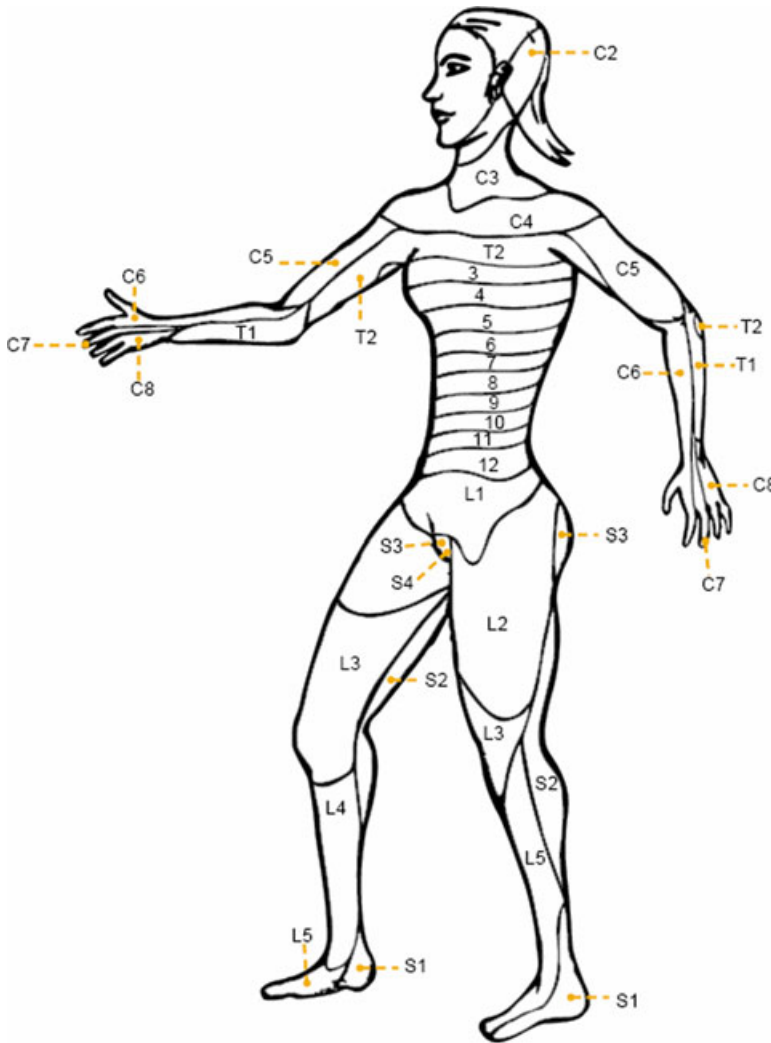


Figure 6. Dermatomes. Source: Candido K & Stevens RA: Intrathecal neurolytic blocks for the relief of cancer pain. *Best Pract Res Clin Anaesthesiol* 2003. **17**(3): 407–428. Reprinted with permission.

roots and rootlets between the spinal cord and the dorsal root ganglion. Predictable, segmental sensory loss occurs by proper patient positioning, correctly selecting the targeted level of injection, and choosing the appropriate neurolytic agent for intrathecal procedures based on baricity (alcohol is hypobaric and phenol is hyperbaric relative to the cerebrospinal fluid). Before performing the block, the appropriate dermatome (Fig. 6) (superficial distribution of nerves) or sclerotome (Fig. 7) (deep distribution of nerves) chart should be reviewed to deter-

mine which nerve roots will be affected.⁷⁴ Relationships between spinal vertebrae and spinal cord levels should also be understood to aid in selecting the appropriate vertebral interspace for the injection (Fig. 8).

Epidural neurolytic blocks can be used as an alternative approach to intrathecal blockade, but the degree of analgesia produced may be less profound. Moreover, intrathecal injections confer greater control over drug spread due to their hypobaricity or hyperbaricity in the cerebrospinal fluid.

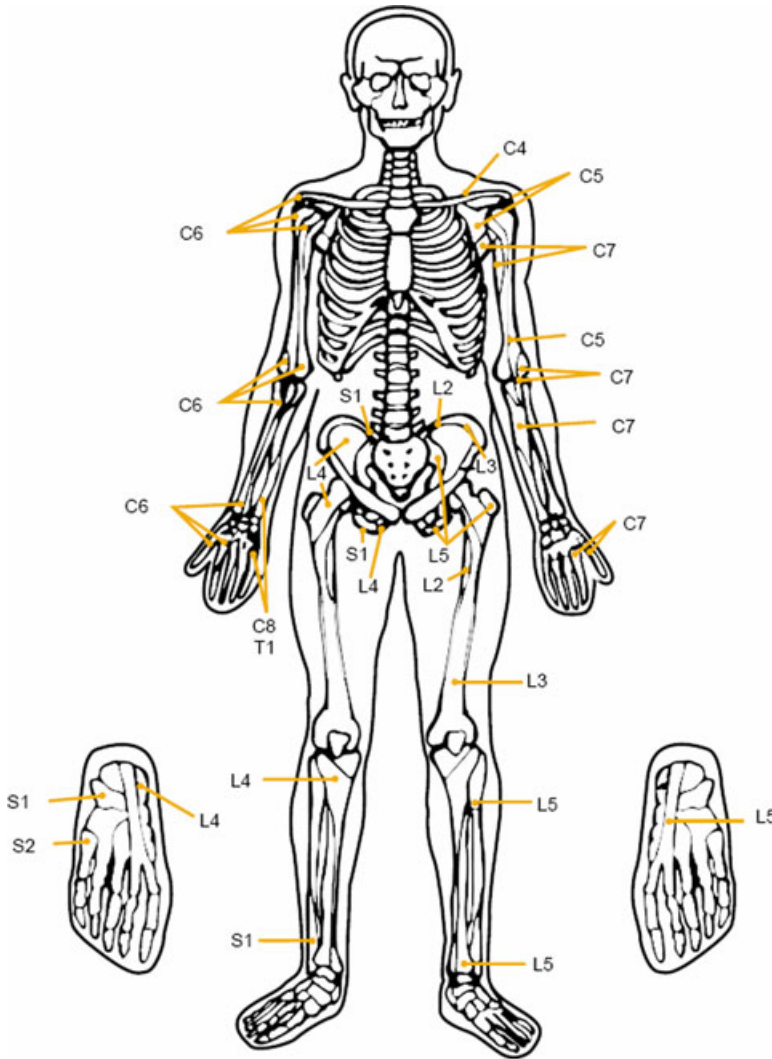


Figure 7. Sclerotomes. Source: Candido K & Stevens RA: Intrathecal neurolytic blocks for the relief of cancer pain. *Best Pract Res Clin Anaesthesiol* 2003. **17**(3): 407–428. Reprinted with permission.

Technique. Most pain specialists perform a prognostic local anesthetic spinal blockade prior to the neurolytic block to confirm the correct level. Choice of neurolytic agent depends on pain location and positioning possibilities for individual patients. The technique for intrathecal (subarachnoid) neurolysis requires careful evaluation to identify the sclerotomal or dermatomal distribution of pain.⁷⁰

The patient is positioned in a lateral decubitus or sitting position and angled 45° toward the prone or supine direction depending on the

agent selected. For example, if alcohol is used, the patient is placed in the lateral position with the affected side uppermost. Alternatively, the patient is positioned with the painful side dependent if phenol is used. In either case, the dorsal rootlets must be positioned in a manner that maximizes flow of neurolytic agent to the targeted anatomic region. The skin is sterilized and local anesthetic is injected along with reasonable sedation for patient comfort and cooperation. A 20–22 gauge spinal needle is inserted into the appropriate vertebral interspace

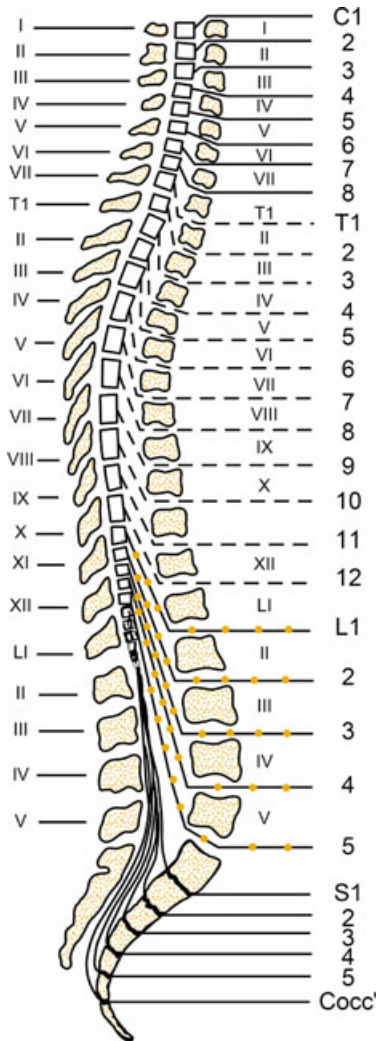


Figure 8. Spinal segments, vertebrae, and respective nerves. Source: Candido K & Stevens RA: Intrathecal neurolytic blocks for the relief of cancer pain. *Best Pract Res Clin Anaesthesiol* 2003. **17**(3): 407–428. Reprinted with permission.

with the bevel pointed down until entry into the subarachnoid space is detected. Alcohol or phenol is then injected in 0.1 mL increments to a total of 0.5 to 0.7 mL for treatment of one to two dermatomal levels. Neurolytic agent is injected only after the patient is properly positioned to localize spread based on the baricity of the solution.⁷¹ Alcohol elicits transitory burning, whereas the local anesthetic properties of phenol prevent the occurrence of this symptom. When conducting a subarachnoid block in re-

gions near or superior to the conus medullaris, care must be taken to avoid inadvertent needle insertion into the substance of the spinal cord.

Side Effects and Complications. There is sparse documentation of complications in the literature. Nonetheless, adverse effects of intrathecal neurolysis may include loss of touch and position sense, rare meningitis, loss of motor function from accidental neurolysis of the ventral rootlets, and postdural puncture headache. The latter is more associated with phenol because larger caliber needles (20 gauge or higher) are required to overcome the viscosity of the solution. Phenol also has a relatively high affinity for the vasculature; therefore, spinal artery thrombosis can rarely occur. Muscle weakness of the extremities and weakness of the rectal and urinary sphincters occur frequently, though transiently. Most complications resolve within a month in nearly three-quarters of patients.⁷⁵ Some studies suggest complication rates as high as 40%, which include spinal headache, paresthesias, and intense numbness of the blocked area.⁷¹

Efficacy. One study evaluated 1908 patients with cancer receiving subarachnoid neurolysis and noted a 78–84% favorable response in patients with somatic pain. It must be noted however, that only 19–24% of patients with visceral pain had positive responses, suggesting that intrathecal neurolytic blockade may less adequately treat pain of visceral origin.⁷⁵ Intrathecal alcohol and phenol seem to produce similar analgesic outcomes. For instance, Bonica and colleagues reported that 61% of 1634 cancer patients receiving intrathecal alcohol neurolysis experienced good pain relief and 58% of 1982 patients receiving phenol described good pain relief.⁷⁶

Thoracic epidural neurolysis with phenol or alcohol has produced analgesia in 80% of cancer pain patients with a maximal duration of greater than 3 months.⁷⁶

Celiac Plexus Block and Neurolysis

Percutaneous, neurolytic celiac plexus block (NCPB) was first described by a German

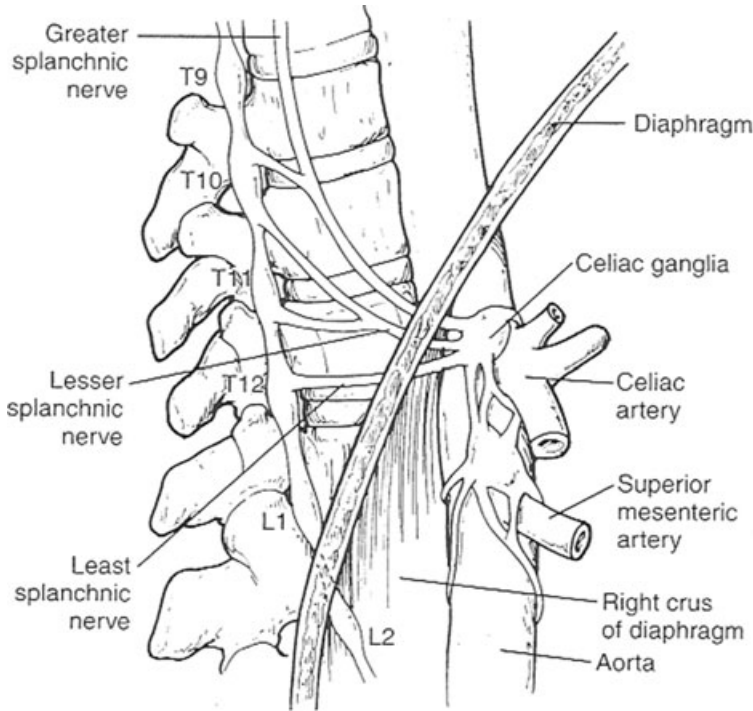


Figure 9. Celiac plexus and splanchnic nerves (lateral view). Source: Waldman SD, Patt RD: Celiac plexus and splanchnic nerve block. In Waldman SD (ed): *Interventional Pain Management*, 2nd ed. Philadelphia, WB Saunders 2001, p. 495. Reprinted with permission.

physician named Kappis in 1919⁷⁷ and then in 1927 by Takats. The procedure became more popular in 1964 when Bridenbaugh published the positive effects of the neurolytic blockade in a series of 41 patients with pain due to pancreatic cancer.⁷⁸ NCPB remains one of the most useful and applicable among the array of neurolytic blocks performed. This technique can effectively control pain due to pancreatic tumors, other primary intra-abdominal tumors, or hepatic metastatic tumors.⁷⁸⁻⁸⁰

Anatomy. The celiac plexus is a network of neuronal ganglia located underneath the diaphragmatic crus in the retroperitoneal space (Fig 9).⁸¹ Primary adjacent structures include the celiac artery and the aorta; the plexus lies anterior and lateral to the aorta,⁸² and immediately inferior to the celiac artery's origin at the superior border of the first lumbar vertebra.⁸³ The greater, lesser, and least splanchnic nerves perforate the diaphragmatic crura and contribute to the celiac plexus. These nerves

are derived from branches of the sympathetic rami communicantes at the T5–T12 segmental levels.⁸⁴ The plexus varies in number of ganglia (2–5), size (0.5–4.5 cm), and location (from the 12th thoracic vertebra to the 2nd lumbar vertebra). The celiac ganglia contain pre- and postganglionic sympathetic efferent fibers, pre-ganglionic parasympathetic fibers, and visceral sensory afferent fibers. The parasympathetic fibers to the plexus derive from the vagus nerve, particularly the right, posterior vagus nerve.⁸⁴ The plexus itself cannot be visualized directly by current imaging modalities, thus correct execution of NCPB relies on full understanding of the surrounding anatomy.

Function. The celiac plexus relays multiple nerve signals. For example, it receives sympathetic fibers from three splanchnic nerves (the greater, lesser, and least), vagal parasympathetic fibers, and visceral afferent fibers. Nociceptive transmission occurs by means of these nerves, which innervate the pancreas, liver,

gallbladder, stomach, spleen, kidneys, intestines, adrenals, and all abdominal vessels except the left colon, rectum, and pelvis.⁸⁶ Accordingly, pain caused by pathologic conditions of these anatomic structures can be interrupted by neurolytic blockade at the level of the celiac plexus or splanchnic nerves.

Techniques. There are several techniques to access the celiac plexus: percutaneous using fluoroscopy or computed tomographic (CT) imaging, surgical, and endoscopic ultrasound. Only the percutaneous approaches are reviewed in this article.

The first percutaneous technique was associated with a relatively high incidence of neurologic complications from excessive posterior spread of agent.⁸⁷ However, subsequent methods have become safer by better limiting the spread of the neurolytic solution to the celiac plexus exclusively, often with the aid of CT guidance.⁸⁸ Four common percutaneous techniques are listed. Three of these represent posterior approaches (transcrural, retrocrural, and transaortic), and one is an anterior technique (anterior approach). Fluoroscopy or CT imaging can be used for all except the anterior approach, which requires CT scan or ultrasound.

Generally, all patients remain in the prone position for 20–30 min after neurolytic injection to reduce the risk of posterior spread of lytic agent and subsequent injury to the spinal canal or neuroforamina. Patients are monitored for symptoms of bleeding, hypotension, or vascular or neurologic injury. Coagulation studies and platelet count should be carefully reviewed prior to the procedure and found to be within normal limits. Needles should be flushed with saline or local anesthetic prior to removal to avoid depositing neurolytic agent along the needle track.

Transcrural Approach. The transcrural approach to the celiac plexus represents one of the earliest attempts to target this structure by placing a needle anterior to the diaphragm in the plane of the aorta. This technique was discovered after evaluating CT images of a needle's trajectory toward the celiac plexus after avoid-

ing the renal parenchyma, major vessels, vertebral body, and lung parenchyma.⁸¹ This procedure requires the patient to lie prone with a pillow beneath the abdomen to reduce the natural lumbar lordosis. Two needles (frequently 22 gauge and 5–7 inches in length) are often used under fluoroscopic guidance or CT imaging (Fig. 10A). The left side needle is inserted 4 cm lateral to midline with the tip approaching the anterolateral aspect of the aorta. The right side needle is inserted 5–10 cm lateral to midline and is directed between the inferior vena cava and the aorta. Each needle traverses the diaphragmatic crus, and eventually lies anterior to this structure. Proper needle location is confirmed with radiographic contrast followed by a test dose of local anesthetic with epinephrine to ensure nonvascular uptake and a non-neuraxial injection. Next, a reasonable volume (for example, 16–20 mL) of local anesthetic is used as a diagnostic block prior to injecting a neurolytic agent (10% phenol or approximately 20–25 mL of 80–100% alcohol). This technique offers a more focused distribution of neurolytic agent and has reduced the incidence of major nerve damage associated with larger volumes and spread of active agent.⁸²

Retrocrural Approach. The retrocrural approach can be slightly modified from the classic technique^{84,85} to include bilateral needle insertion that initially contacts the T12 or L1 vertebral bodies and is ultimately advanced to the anterolateral surface of T12. Essentially, the retrocrural technique blocks the thoracic splanchnic, vagal, and sensory afferent fibers that compose the celiac plexus.⁸⁹ This block is often considered when tumor burden is extensive in the pre-aortic region, thus limiting adequate spread of neurolytic agent over the celiac ganglia. Two 20–22 gauge, 5–7 inch needles are inserted bilaterally, inferior to the 12th rib, and no more than 7.5 cm lateral to midline. Once the needles contact the vertebral body, they each can be “walked-off” and advanced 1–3 cm or until aortic pulsations are transmitted to the left side needle. Appropriate needle course is guided by fluoroscopy or CT imaging.

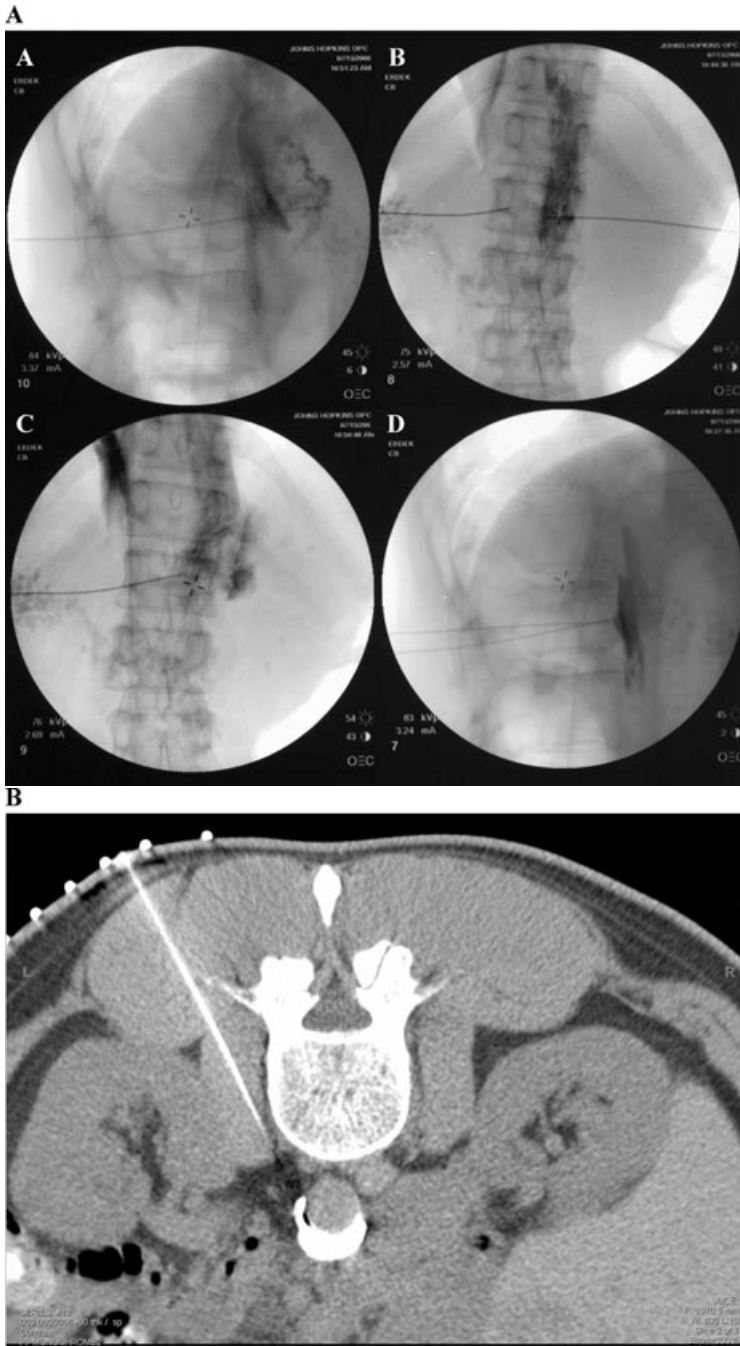

Figure 10. (A) Fluoroscopically guided celiac plexus neurolytic block (AP and lateral views). (B) CT-guided celiac plexus neurolytic block (transaortic approach).

CT guidance will demonstrate the needles' location with respect to pertinent structures, such as the vertebral body, aorta, inferior vena cava, kidney, and diaphragm. Both needles remain

posterior to the diaphragmatic crura. Splanchnic nerve blocks require passing the needle to the lateral edge of the middle to superior aspect of the T12 vertebral body.⁸⁴ Near the

upper border of T12, just superior and posterior to the crura, the splanchnic nerves lie within a supracrural compartment, which helps to confine solution alongside the anterolateral borders of the T10–T12 vertebral bodies.⁸⁴ Similar to the transcrural method, steps are taken to verify position with radiographic contrast and local anesthetic with epinephrine before producing a diagnostic blockade with local anesthetic followed by neurolytic injection. However, slightly lower total volumes of local anesthetic (e.g., 10–16 mL) and neurolytic agent (e.g., 10–15 mL of 10–12% phenol or 80–100% alcohol) are typically injected.⁹⁰ The solution travels superiorly and posteriorly around the splanchnic nerves, limited inferiorly by the crura, laterally by the parietal pleura, and anteriorly by the great vessels.⁸⁴

Transaortic Approach. The transaortic technique^{88,91} involves the insertion of a single needle from a posterolateral entry site and passing it through the aorta to the celiac plexus (Fig. 10B). Data suggest that this technique compares favorably to the classic approach in safety and efficacy.^{88,91} The presence of aortic aneurysm, significant mural calcifications, or mural thrombus is a contraindication to this approach.

Patients are placed prone with a pillow under the abdomen to flex the lumbar spine. Images are taken between T12 and L2 to identify the aorta, celiac artery, and superior mesenteric vessels. A 20–22 gauge, 7-inch needle is inserted 4–7 cm to the left of midline below the 12th rib. If the transverse process of T12 or L1 is encountered, the needle is redirected more superiorly or inferiorly. If the needle encounters the vertebral body, it is redirected until it slips off the lateral aspect of the bone. A loss of resistance is felt as the posterior aortic wall is penetrated, and arterial blood is observed upon stylet removal. A loss of resistance syringe containing sterile, preservative-free saline is attached to the needle, which is slowly advanced through the aorta with constant, gentle pressure on the plunger. As the needle penetrates the anterior wall of the aorta, an increase in resistance on the plunger

occurs. A loss of resistance then ensues once the needle extends past the aortic wall and into the retroperitoneal area, adjacent to the celiac plexus. Three to 5 mL of radiographic contrast is injected to confirm proper spread of solution anterior to the crura and along pre-aortic tissue planes. Injections of a test dose of local anesthetic with epinephrine, plain local anesthetic (e.g., 6–8 mL), and 15 mL of absolute alcohol follow in succession. Aspiration applied to the needle must be performed prior to injecting any drugs so that the clinician can avoid intravascular position of the needle tip.

Anterior Approach. With the patient in a supine prone position, a single spinal needle is placed inferior to the xiphoid process. Under CT guidance or ultrasonographic guidance, the needle can be directed to the pre-aortic region of the celiac plexus. Careful needle positioning is mandatory to avoid injury to the liver, bowel, pancreas, and superior mesenteric and celiac arteries using this technique.⁹²

Side Effects and Complications. NCPB can be associated with several complications, including pain at the site of injection causing backache, hypotension, hematuria from renal injury, pneumothorax, diarrhea, and impotence.⁹³ The minor sequelae, hypotension and diarrhea, are transient and common to all approaches due to the occurrence of sympathetic blockade. For instance, generalized vasodilatation and prolonged diarrhea can result from loss of sympathetic tone to the vasculature and gastrointestinal tract.⁷⁹ Hypotension can be attenuated with proper preloading of crystalloid solution.

One of the most serious complications of NCPB, paraplegia may occur in approximately 1% of patients undergoing the retrocrural (classic) technique,⁹⁴ but the incidence is reported to be as low as approximately 1 per 700 in a retrospective analysis.⁹³ This survey studied 2730 patients and found only four cases of major complications, which included bowel or bladder dysfunction and paralysis.⁹³ Theoretical mechanisms leading to paralysis involve ischemia of the anterior spinal cord from

alcohol-induced vasospasm or mechanical injury to the artery of Adamkiewicz.^{95,96}

Some studies indicate that unilateral celiac plexus block, in which half the typical volume of neurolytic agent is injected may reduce procedural pain and diarrhea while still providing adequate pain control.⁹⁷

Expert consensus considers radiographic or ultrasonographic guidance mandatory for safe and correct needle placement while performing a celiac plexus block. Whether CT or fluoroscopy is the best imaging modality has yet to be determined,^{98,99} though CT allows three-dimensional views of needle positioning compared to two-dimensional views afforded by fluoroscopy.

Efficacy. Short-term efficacy of NCPB at 1 week is noted to be as high as 90% in one RCT comparing the effects of NCPB to a non-steroidal anti-inflammatory drug (NSAID)-opioid regimen in patients with pancreatic cancer pain.¹⁰⁰ In fact, NCPB reduced opioid consumption and associated adverse effects for 4 weeks with continual benefit until death in patients with advanced disease.

In a similar RCT of 24 patients with pancreatic cancer, one group was given an NCPB while the control group received pharmacological therapy for pain.¹⁰¹ Adjunctive treatment for pain control was provided by adherence to the WHO 3-step analgesic ladder for each group, and patients were followed until death. Although the study did not find a statistical difference in pain relief between the two groups, the opioid and NSAID consumption of the neurolytic group was significantly less than that of the group receiving pharmacological therapy. Furthermore, negligible sequelae resulted from the NCPB. Given the clinical benefit associated with the reduction in analgesic consumption, the authors concluded that NCPB can effectively treat pancreatic cancer pain.

A meta-analysis of NCPB for pancreatic and other intra-abdominal cancer pain demonstrates that 90% of patients receiving this therapy reported partial to complete pain relief at 3 months, while 70–90% of patients had partial

to complete pain relief at the time of death, even if death occurred more than 3 months after the NCPB.⁷⁹

Failures. Anatomic changes that results from the tumor¹⁰² or prior surgery¹⁰³ may reduce the success of NCPB in alleviating pain. Further, metastatic disease, tumor extension beyond the neural domain of the celiac plexus, and nerve regrowth may yield failures in pain control despite a properly blocked celiac plexus.⁸⁶

Superior Hypogastric Plexus Block and Neurolysis

Anatomy. In general, dual projections from the thoracolumbar and sacral portions of the spinal cord innervate the pelvis and then coalesce into neuronal plexuses that send fibers throughout the pelvis. The pelvic viscera receive neurons from the sympathetic (thoracolumbar) and parasympathetic (craniosacral) nervous systems. Visceral afferent fibers traveling in the sympathetic trunk contain their cell bodies in the dorsal root ganglia between T10–L2. Likewise, visceral afferent fibers traveling with parasympathetic fibers contain their cell bodies in the dorsal root ganglia arising from S2–S4. These fibers create a neuronal network called the SHP, which lies anterior to the sacral promontory at the L5–S1 level (Fig. 11).

The sympathetic fibers that contribute to the SHP originate from the anterolateral cell column of the spinal cord at the level of T11–12. Via the lower thoracic and upper lumbar paravertebral sympathetic ganglion, sympathetic fibers communicate to either the aortic plexus or the sacral sympathetic trunk. The aortic plexus gives rise to the SHP and inferior hypogastric plexus.¹⁰⁴ The SHP itself is located retroperitoneally in the subserous fascia of the common iliac bifurcation, which lies in proximity to the lower third of L5 and upper third of the S1 vertebral bodies.¹⁰⁵

Function. The SHP transmits sensory information from the bladder, rectum, prostate, testes, vagina, uterus, ovaries, and descending and sigmoid colon. Additionally, the SHP sends

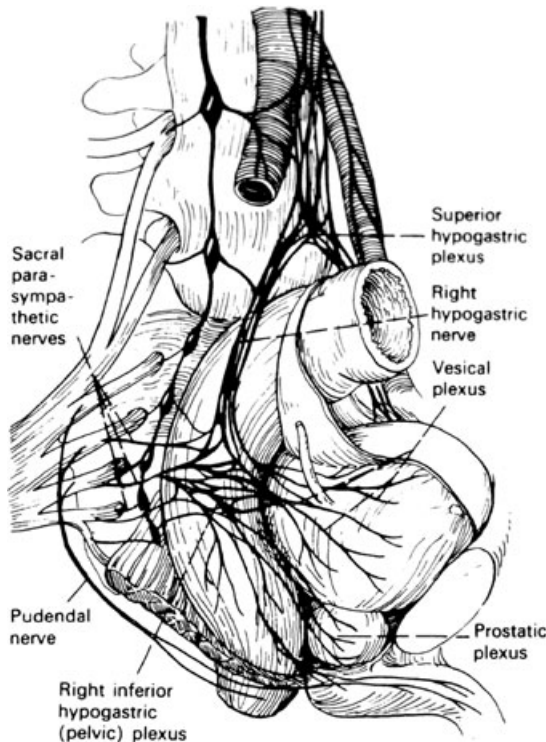


Figure 11. Superior hypogastric plexus (oblique view). Source: Bonica's Management of Pain, 3rd edition, p. 1363. Reprinted with permission.

sensory fibers to the pudendal and ilioinguinal nerves which innervate the perineum, anus, penis, scrotum, and clitoris. The SHP also contributes to sympathetic regulation of the pelvic organs with respect to sexual function.¹⁰⁶

Techniques. While SHP ablation can be performed invasively by laparotomy or laparoscopy, minimally invasive, percutaneous modalities will be the focus of this discussion.

The percutaneous approach was initially described by Plancarte *et al.* in 1990 for the treatment of pelvic cancer pain.¹⁰⁷ Since that time, SHP blocks/neurolysis have been successfully used for the relief of pain in both cancer and noncancer conditions.^{107–109} Either fluoroscopic or CT-guided^{110,111} imaging can be selected for any of the common anatomic approaches to the SHP: posterior, transdiscal (posterior), or anterior.

Posterior Approach. With the patient in the prone position, the L4–L5 interspace is approx-

imated using the iliac crest and spinous process as anatomic guides.¹⁰⁷ A pillow beneath the pelvis aids in flattening the lumbar lordosis. After standard aseptic preparation and dressing, an area 5–7 cm bilateral to midline at the L4–L5 interspace is anesthetized with local agent and a 7-inch, 22-gauge short-beveled needle is inserted toward the midline at 30° caudad and 45° medially. Each needle is guided to the anterolateral aspect of L5 vertebral body. If the transverse process or vertebral body of L5 is encountered, the needle may be redirected or “walked off” these surfaces so the needle tip is ultimately positioned 1 cm beyond the vertebral body. A loss of resistance may be felt once the needle tip has exited the anterior fascial boundary of the ipsilateral psoas muscle. Either fluoroscopy or sequential CT imaging is used during needle passage to verify correct positioning.

Once the needle tips are verified to be at the L5–S1 junction and just beyond the anterolateral border of the vertebral body, 3–4 mL of radiographic contrast are injected to confirm correct needle position. Lateral imaging should demonstrate a smooth posterior contour of contrast along the L5–S1 junction, and anterior–posterior (AP) imaging will show flow of contrast at the midline region. A total of 15–20 mL of local anesthetic (for instance, 0.25% bupivacaine) is then injected for diagnostic purposes. A “test” dose of local anesthetic with epinephrine may be injected as an additional precaution before hypogastric plexus blockade with local anesthetic or neurolytic agent. For neurolytic blocks, 5–8 mL of 10% phenol through each needle has proved efficacious,^{106,107} while a total of 15–30 mL of 100% alcohol has shown to be effective when using this lytic agent.^{112,113}

A single-needle posterior approach with CT guidance was described by Waldman and colleagues that suggests easier, safer, and more accurate needle placement for blocking the SHP than the two-needle posterior technique described previously.¹¹⁴ However, some pain specialists have reported greater success with the

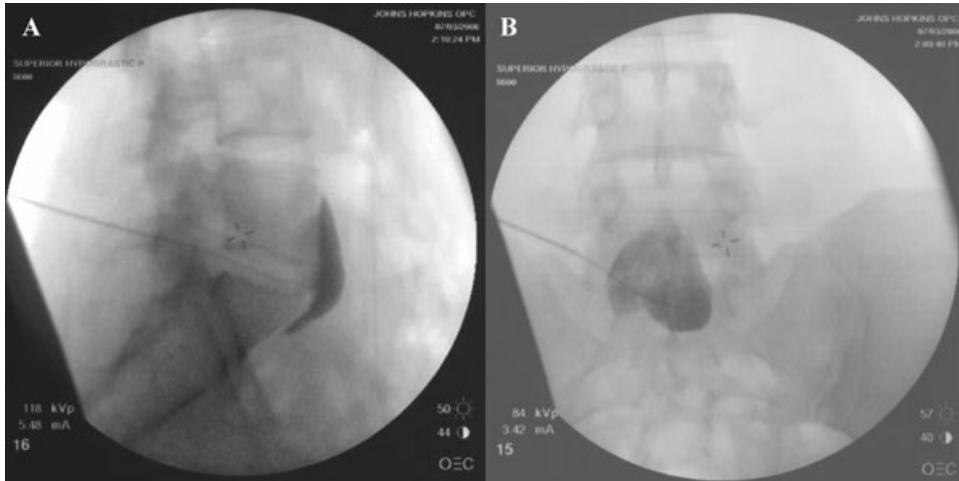


Figure 12. (A) Superior hypogastric plexus neurolytic block, transdiscal approach, fluoroscopically guided (lateral view). (B) Superior hypogastric plexus block, transdiscal approach, fluoroscopically guided (AP view).

dual needle, posterior approach in patients with pelvic cancer pain.¹⁰⁸

Transdiscal Approach. The transdiscal approach is similar to the technique described by Erdine and associates¹¹⁵ with slight modifications¹¹⁴ (Fig. 12A and B). The patient is placed in the prone position in like manner to the posterior approach. The L5–S1 level is identified with imaging. If fluoroscopy is used, the scope is directed 15–25° obliquely and angled cephalad to obtain the best image of the intradiscal space. Needle insertion is approximately 5–7 cm from the midline. A 22-gauge, 7-inch needle is then advanced through the disc under imaging guidance. One-half millimeters of radiographic contrast may be injected to verify intradiscal position. Next, the needle is advanced through the disc and into the retroperitoneal space. Three milliliters of radiographic contrast verifies proper position and spread of agent under imaging. A total of 15 to 20 mL of local anesthetic can be used as a diagnostic or prognostic tool. Five milliliters of 10% phenol through each needle is effective in controlling pelvic pain associated with cancer,¹¹⁵ though clinical experience suggests that 15–30 mL of 80–100% alcohol may equivalently treat pelvic cancer pain. Either 0.5 mL of air, saline, or local anesthetic should be given through the

needle before withdrawal to prevent neurolytic spread within the disc or soft tissues of the lower back. Prophylactic antibiotics (such as cefazolin) should be considered intravenously and intradiscally to prevent discitis.¹¹⁶

Anterior Approach. The anterior approach to the SHP has been described using fluoroscopy¹¹⁵ and CT guidance.^{109–111}

The anterior approach using fluoroscopy¹¹⁶ targets the SHP proximal to the bifurcation of the iliac vessels by entering the skin midline about 2–3 cm inferior to the umbilicus with the patient in 15° Trendelenberg and supine. A 22-gauge, 6-inch needle is inserted in the midline toward the L5 vertebral body. Once the needle tip reaches the inferior two-thirds of L5, the needle is aspirated to rule out arterial or venous puncture. Aspiration may also be performed to exclude ureteral or gut injury. Radiographic contrast is injected to verify spread of solution in the AP and lateral views. A total of 20–30 mL of 0.25% bupivacaine is then deposited.

The CT-guided anterior approaches essentially use a 20–23 gauge, 4–5 inch needle that is inserted at the midline, between the umbilicus and the symphysis pubis after scanning from L3–S2.^{110,111} The needle tip is positioned anterior to the left iliac vein, between the iliac

vessels, and inferior to the aortic bifurcation. Following negative aspiration, 2 mL of radiographic contrast is injected. Assuming proper spread, 15 mL of local anesthetic (often 0.25% bupivacaine) is deposited. For neurolytic purposes, between 10–20 mL of alcohol, 60% and greater, has been used successfully.^{110,111} In one study, systemic antibiotics (such as cefuroxime 2.25 g) were provided as prophylaxis against needle perforation of the small intestine.¹¹¹

Surgical Approach. Surgical techniques were initially developed to address pelvic pain by presacral neurectomy (cutting or excising nerve fibers to interrupt neural input) via laparoscopy¹¹⁷; however, there can be numerous complications associated with this method including injury to lymphatics,¹¹⁸ major vessels (including iliac vessels), bowel, bladder, and ureters, as well as the onset of increased pain.¹¹⁹ Laparoscopic presacral neurectomy is noted to be a difficult procedure, so neurectomy may be more effectively replaced by chemical neurolysis performed either laparoscopically or percutaneously.¹¹⁷

Side Effects and Complications. Percutaneous SHP neurolysis has few documented complications associated with the posterior, transdiscal, or anterior approaches. In one of the larger studies, there were no significant complications or adverse effects.¹²⁰ In an RCT comparing early and late SHP neurolysis with medical management, acute hypotension and localized tenderness were noted as the most significant adverse effects, both of which resolved spontaneously with minimal intervention.¹¹² Possible complications include bladder puncture, retroperitoneal hematoma (including damage to the iliac vessels), needle injury to the L5 or S1 nerve roots,¹²¹ and mechanical or chemical injury to the lumbar plexus and genitofemoral nerve.¹²² The transdiscal approach may be associated with discitis or mechanical damage to the disc, though no complications were reported in the study by Erdine and colleagues.¹¹⁵ The literature has shown the risk of discitis to be about 1–4% with transdiscal needle inser-

tion.¹¹⁵ The anterior technique risks injury to the bowel, small intestine, bladder, and iliac vessels; however, none of the more recent investigations report relevant complications.^{110,111,116} Advocates of the anterior approach cite its superiority over alternative approaches because the former is simpler, and reduces the risk of injuring the aorta, iliac veins, or lumbar nerves.^{109,110}

Efficacy. In a large trial of 227 patients with pelvic pain secondary to gynecological, colorectal, or genitourinary cancer, 79% of patients had a positive response to a diagnostic SHP block, and 72% reported effective pain relief and significant reduction in opioid consumption following neurolytic block.¹²⁰ At the 6-month follow-up, 69% had continued pain relief, with a 67% reduction in opioid use for pain control.¹²⁰

In the only RCT comparing neurolytic SHP with opioid therapy, neurolytic SHP was found to significantly reduce cancer pain intensity, opioid consumption, and drug-induced adverse effects while enhancing quality of life.¹¹²

Failures. Diagnostic or prognostic injection of local anesthetic helps to predict whether chemical neurolysis will benefit the patient. In spite of positive diagnostic tests, failures occur with neurolysis. For instance, some patients experience no pain relief, report minimal relief, or report that pain relief is transient. However, transient pain relief is still reported as beneficial with a modest (45%) reduction in opioid usage.¹²⁰ CT-guided techniques and larger volumes of neurolytic agent may reduce treatment failures.

Ganglion Impar Block and Neurolysis

The ganglion impar (GI) block was first described by Plancarte *et al.* in 1990 for the treatment of intractable perineal cancer pain of sympathetic etiology.¹²³ Alternative approaches have been reported during the intervening period with successful outcomes.^{124–127} The primary indications for this procedure are sustained visceral or sympathetically maintained perineal pain from cancer (especially anal or

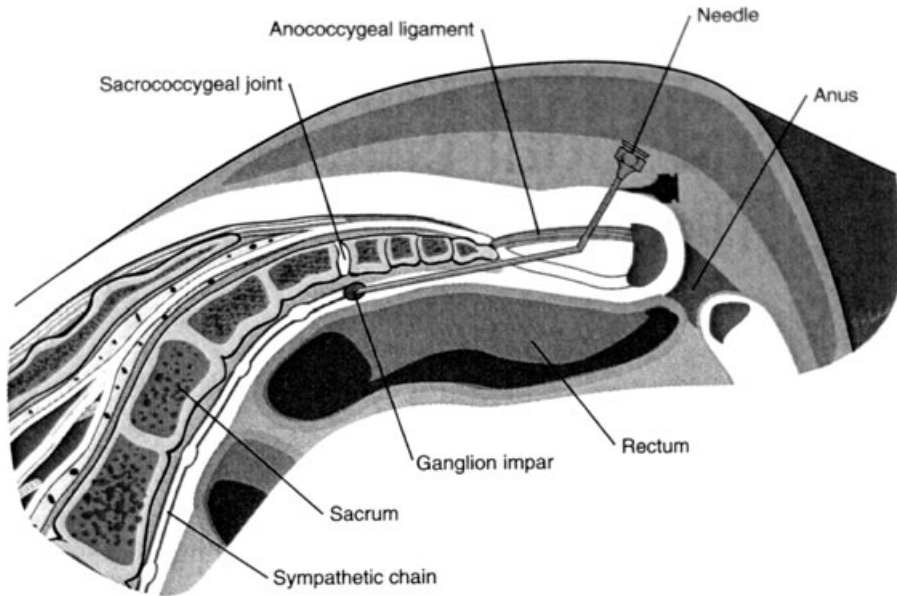


Figure 13. Ganglion impar and surrounding structures. Source: Waldman S: *Atlas of Interventional Pain Management*, 2nd edition, p. 421, Elsevier, 1998. Reprinted with permission.

rectal cancer) or noncancer (e.g., coccydynia) origin.

Anatomy. The GI is a single, semicircular, retroperitoneal structure often positioned mid-line at the level of the sacrococcygeal junction and represents the termination of the paravertebral sympathetic chains (Fig. 13). The GI contains grey rami communicantes that travel to sacral and coccygeal nerves, though the precise neural network is incompletely understood.

Until recently, the impar's location was inconsistently described; it ranged from the anterior aspect of the sacrococcygeal joint^{128,129} to the body or tip of the coccyx.¹³⁰ A recent anatomic study has identified the GI as more commonly located anterior to the lower portion of the first coccygeal body. This location was determined after micro-anatomic dissection of 50 sacrococcygeal structures.¹³⁰

Function. The GI contains visceral afferent fibers that innervate the perineum, distal part of the rectum, anus, distal urethra, distal third of the vagina, and vulva.¹³¹ The impar seems to lack white rami communicantes. Patients often complain of burning sensations and uri-

nary and rectal urgency associated with GI dysfunction.

Techniques. Four techniques are described in the literature for placement of the GI block: anococcygeal, trans-sacrococcygeal, coccygeal transverse process, and intercoccygeal. For all four techniques, proper needle placement in the retroperitoneal space is usually noted with the formation of a "comma sign" produced by 1–2 mL of radiographic contrast in lateral fluoroscopic view.^{123,126} Next, 1–3 mL or 4–8 mL of preservative-free local anesthetic (such as 0.25% bupivacaine) is injected for diagnostic or prognostic purposes, depending on needle proximity to the GI. Therapeutic neurolysis is accomplished with 1–2 mL of 10% phenol or absolute alcohol¹²⁵ or 4–8 mL of 10% phenol,¹²³ again based on the proximity of the needle tip to the GI. For example, the closer the needle tip is positioned to the GI, the lower the volume of injectate is required.

A novel approach has been described using radiofrequency ablation of the GI in lieu of chemical neurolysis for the treatment of noncancer-related perineal pain.¹³¹ In the

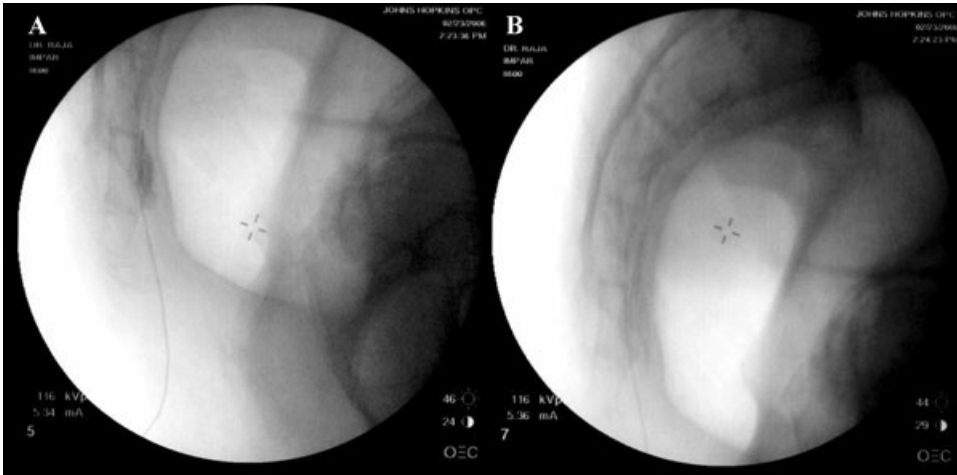


Figure 14. Ganglion impar neurolytic block, anococcygeal approach, fluoroscopically guided (lateral views).

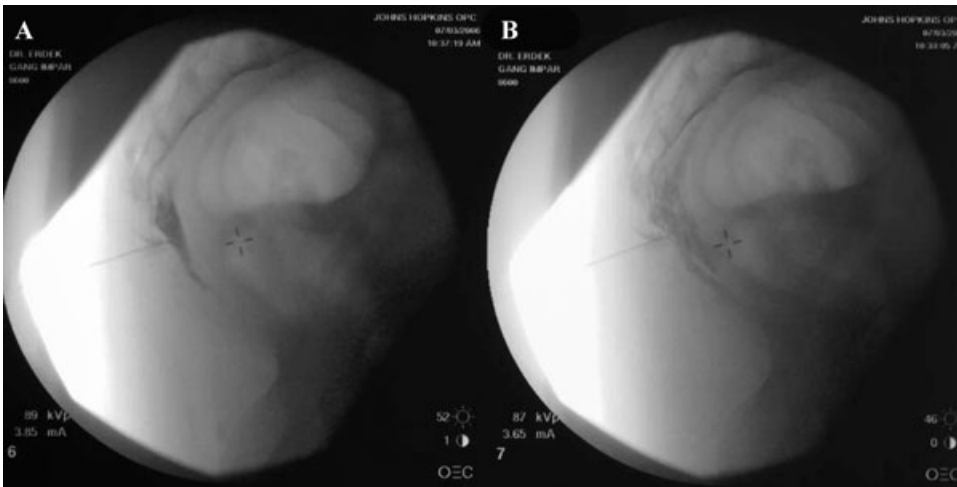


Figure 15. Ganglion impar neurolytic block, trans-sacrococcygeal approach, fluoroscopically guided (lateral views).

future, this technique may hold promise for alleviating pain of malignant origin while reducing the risk of complications associated with chemical neurolysis.

Anococcygeal Approach. This approach was first described by Plancarte in 1990 using a bent needle technique^{71,123} (Figs. 13 and 14). With the patient in the lateral decubitus position and knees bent against the abdomen, the anococcygeal ligament is palpated inferior to the coccyx. A 60° curved, 22 gauge, 3.5-inch needle is placed through the anococcygeal ligament and directed cephalad with a slightly posterior an-

gle to minimize the risk of rectal perforation. Proper position of the needle is noted when the tip has reached the sacrococcygeal junction. The practitioner may perform a continuous rectal exam to confirm the integrity of the rectum. A similar technique has been modified with the patient in a frog-legged position to extend the distance from the anococcygeal ligament to the impar in order to eliminate the need for needle angulation.¹³²

Trans-Sacrococcygeal Approach. The sacrococcygeal approach was first described by Wemm and colleagues in 1995.¹³³ In this technique, the

patient is placed in the lateral decubitus position with both knees flexed, and fluoroscopy is used to identify the sacrococcygeal joint (Fig. 15). A 22-gauge, 3.5-inch needle is used to penetrate midline through the sacrococcygeal ligament and into the retroperitoneal space. Local anesthetic or neurolytic agent is injected in a quantity sufficient to cover the sacrococcygeal joint and to ensure blockade of the GI.

Intercoccygeal Approach. This technique has been described most recently (2006) and entails the insertion of a 22-gauge, 2-inch needle through the space between the first and second coccygeal bones.^{124,125} After proper spread of radiographic contrast, 1 mL of 4% lidocaine is deposited as a prognostic test prior to injecting 4 mL of 100% alcohol.

Coccygeal Transverse Approach. In 2004, Huang reported this technique as an alternative to the sacrococcygeal approach.¹³⁴ Needle entry is inferior to the transverse process of the coccyx. The patient is placed in the prone or lateral position, and a bent or curved 22-gauge, 3.5-inch needle is directed superiorly and medially toward the sacrococcygeal junction. If the coccyx is encountered, the needle is repositioned inferiorly and walked off the bone. The needle is inserted near the anterior surface of the coccyx until it reaches the sacrococcygeal junction. Local anesthetic and/or neurolytic agent can be injected after correct needle position is verified by fluoroscopy.

Side Effects and Complications. There are currently no reported complications in the literature^{105,135}; however, theoretical risks include needle breakage, failure of the block/neurolysis (e.g., secondary to tumor spread), rectal perforation, periosteal injection, sacral nerve root injury, epidural injection, and motor, sexual, bowel, or bladder dysfunction from accidental spread of neurolytic agent.^{126,131}

Clinical Effectiveness. Two prospective studies have reported good efficacy of neurolytic blockade of the GI using 6% phenol for unremitting perineal pain due to cancer.^{123,136} In another

study, the effects of radiofrequency ablation of the GI produced a 50% decrease in pain scores, with average duration of 2.2 months and no complications.¹³¹

Failures. Failures can be attributed to the variable anatomic location of the GI and incomplete understanding of visceral nociceptive processing and specific neural connections that lead to and from the GI.¹³¹

Conclusion

A significant number of patients with cancer may suffer from considerable pain at some point during their disease. Application of the WHO analgesic guidelines is a critical component to managing cancer pain effectively. However, healthcare professionals must consider the array of interventional pain-relieving strategies currently available that can substantially improve the quality of life of patients suffering from cancer pain. These procedural interventions include epidural and intrathecal infusion therapies, IDDS, and neuraxial interventions, such as celiac plexus, SHP, and GI neurolytic blocks. Many of these procedures offer rapid and effective analgesia with less toxicity than oral or parenteral agents, permit dose reductions of systemic analgesics, serve as an alternative to cases of refractory pain, and enhance performance status and quality of life of patients with cancer pain. Some interventions (such as IDDS and celiac plexus neurolysis) even confer a survival benefit among those patients treated with the therapy.^{45,69} Clearly, pain practitioners face complex clinical challenges while treating cancer pain patients. Today, interventional pain-relieving approaches should be considered as a critical component of a multifaceted therapeutic program of cancer pain relief.

Conflicts of Interest

The authors declare no conflicts of interest.

References

1. Brescia, F.J. *et al.* 1992. Pain, opioid use, and survival in hospitalized patients with advanced cancer. *J. Clin. Oncol.* **10**: 149–155.
2. Cleeland, C.S. *et al.* 1994. Pain and its treatment in outpatients with metastatic cancer. *N. Engl. J. Med.* **330**: 592–596.
3. Portenoy, R.K. *et al.* 1992. Pain in ambulatory patients with lung or colon cancer. Prevalence, characteristics, and effect. *Cancer* **70**: 1616–1624.
4. Tolle, S.W. *et al.* 2000. Family reports of barriers to optimal care of the dying. *Nurs. Res.* **49**: 310–317.
5. Berry, P.H. & J.L. Dahl. 2000. The new JCAHO pain standards: implications for pain management nurses. *Pain. Manag. Nurs.* **1**: 3–12.
6. WHO. 1998. Cancer Pain Release. Available from: <http://www.whocancerpain.wisc.edu/> (accessed Nov. 9, 2007).
7. Zech, D.F. *et al.* 1995. Validation of World Health Organization Guidelines for cancer pain relief: a 10-year prospective study. *Pain* **63**: 65–76.
8. Committee, W.E. 1990. Cancer pain relief and palliative care. In World Health Organ. Tech. Rep. Ser., W.H. Organization, Editor. 1–75.
9. Levy, R.M. 1996. Pharmacologic treatment of cancer pain. *N. Engl. J. Med.* **335**: 1124–1132.
10. Cherny, N.I. & K.M. Foley. 1997. Nonopioid and opioid analgesic pharmacotherapy of cancer pain. *Otolaryngol. Clin. North Am.* **30**: 279–306.
11. Pappagallo, M. 2001. Incidence, prevalence, and management of opioid bowel dysfunction. *Am. J. Surg.* **182**(5A Suppl): 11S–18S.
12. Walsh, T.D. 1990. Prevention of opioid side effects. *J. Pain Symptom. Manage.* **5**: 362–367.
13. Bruera, E. *et al.* 1992. The use of methylphenidate in patients with incident cancer pain receiving regular opiates. A preliminary report. *Pain* **50**: 75–77.
14. Meuser, T. *et al.* 2001. Symptoms during cancer pain treatment following WHO-guidelines: a longitudinal follow-up study of symptom prevalence, severity and etiology. *Pain* **93**: 247–157.
15. Miaskowski, C. *et al.* 2001. Lack of adherence with the analgesic regimen: a significant barrier to effective cancer pain management. *J. Clin. Oncol.* **19**: 4275–4279.
16. Bruera, E. *et al.* 1996. Opioid rotation in patients with cancer pain. A retrospective comparison of dose ratios between methadone, hydromorphone, and morphine. *Cancer* **78**: 852–857.
17. de Stoutz, N.D., E. Bruera & M. Suarez-Almazor. 1995. Opioid rotation for toxicity reduction in terminal cancer patients. *J. Pain Symptom. Manage.* **10**: 378–384.
18. Miguel, R. 2000. Interventional treatment of cancer pain: the fourth step in the World Health Organization analgesic ladder? *Cancer Control.* **7**: 149–156.
19. Agency for Health Care Policy and Research Rockville, Maryland. 1994. Management of cancer pain guideline overview. *J. Natl. Med. Assoc.* **86**: 571–573, 634.
20. Hogan, Q. *et al.* 1991. Epidural opiates and local anesthetics for the management of cancer pain. *Pain* **46**: 271–279.
21. Smitt, P.S. *et al.* 1998. Outcome and complications of epidural analgesia in patients with chronic cancer pain. *Cancer* **83**: 2015–2022.
22. Bedder, M.D., K. Burchiel & A. Larson. 1991. Cost analysis of two implantable narcotic delivery systems. *J. Pain Symptom. Manage.* **6**: 368–373.
23. Crul, B.J. & E.M. Delhaas. 1991. Technical complications during long-term subarachnoid or epidural administration of morphine in terminally ill cancer patients: a review of 140 cases. *Reg. Anesth.* **16**: 209–213.
24. Bahar, M., M. Rosen & M.D. Vickers. 1984. Chronic cannulation of the intradural or extradural space in the rat. *Br. J. Anaesth.* **56**: 405–410.
25. Baker, L. *et al.* 2004. Evolving spinal analgesia practice in palliative care. *Palliat. Med.* **18**: 507–515.
26. Sjoberg, M. *et al.* 1991. Long-term intrathecal morphine and bupivacaine in “refractory” cancer pain. I. Results from the first series of 52 patients. *Acta Anaesthesiol. Scand.* **35**: 30–43.
27. Nitescu, P. *et al.* 1992. Bacteriology, drug stability and exchange of percutaneous delivery systems and antibacterial filters in long-term intrathecal infusion of opioid drugs and bupivacaine in “refractory” pain. *Clin. J. Pain.* **8**: 324–337.
28. Nitescu, P. *et al.* 1998. Continuous infusion of opioid and bupivacaine by externalized intrathecal catheters in long-term treatment of “refractory” nonmalignant pain. *Clin. J. Pain.* **14**: 17–28.
29. Nitescu, P. *et al.* 1991. Long-term, open catheterization of the spinal subarachnoid space for continuous infusion of narcotic and bupivacaine in patients with “refractory” cancer pain. A technique of catheterization and its problems and complications. *Clin. J. Pain.* **7**: 143–161.
30. Nitescu, P. *et al.* 1990. Epidural versus intrathecal morphine-bupivacaine: assessment of consecutive treatments in advanced cancer pain. *J. Pain Symptom. Manage.* **5**: 18–26.
31. Penn, R.D. *et al.* 1984. Cancer pain relief using chronic morphine infusion. Early experience with a programmable implanted drug pump. *J. Neurosurg.* **61**: 302–306.

32. Sjoberg, M. *et al.* 1992. Neuropathologic findings after long-term intrathecal infusion of morphine and bupivacaine for pain treatment in cancer patients. *Anesthesiology* **76**: 173–186.
33. Dahm, P. *et al.* 1998. Efficacy and technical complications of long-term continuous intraspinal infusions of opioid and/or bupivacaine in refractory nonmalignant pain: a comparison between the epidural and the intrathecal approach with externalized or implanted catheters and infusion pumps. *Clin. J. Pain* **14**: 4–16.
34. Gestin, Y., A. Vainio & A.M. Pegurier. 1997. Long-term intrathecal infusion of morphine in the home care of patients with advanced cancer. *Acta Anaesthesiol. Scand.* **41**(1 Pt 1): 12–17.
35. Krames, E.S. & R.M. Lanning. 1993. Intrathecal infusional analgesia for nonmalignant pain: analgesic efficacy of intrathecal opioid with or without bupivacaine. *J. Pain Symptom. Manage.* **8**: 539–548.
36. Hassenbusch, S. *et al.* 2002. Management of intrathecal catheter-tip inflammatory masses: a consensus statement. *Pain Med.* **3**: 313–323.
37. Cabbell, K.L., J.A. Taren & O. Sagher. 1998. Spinal cord compression by catheter granulomas in high-dose intrathecal morphine therapy: case report. *Neurosurgery* **42**: 1176–1180; discussion 1180–1181.
38. Langsam, A. 1999. Spinal cord compression by catheter granulomas in high-dose intrathecal morphine therapy: case report. *Neurosurgery* **44**: 689–691.
39. McMillan, M.R., T. Doud & W. Nugent. 2003. Catheter-associated masses in patients receiving intrathecal analgesic therapy. *Anesth. Analg.* **96**: 186–190, table of contents.
40. Corning, J. 1885. Spinal anaesthesia and local medication of the cord. *N. Y. Med. J.* **42**: 483–485.
41. Brill, S., G.M. Gurman & A. Fisher. 2003. A history of neuraxial administration of local analgesics and opioids. *Eur. J. Anaesthesiol.* **20**: 682–689.
42. Wallace, M. & T.L. Yaksh. 2000. Long-term spinal analgesic delivery: a review of the preclinical and clinical literature. *Reg. Anesth. Pain Med.* **25**: 117–157.
43. Prager, J.P. 2002. Neuraxial medication delivery: the development and maturity of a concept for treating chronic pain of spinal origin. *Spine* **27**: 2593–2605; discussion 2606.
44. Vainio, A. & A. Auvinen. 1996. Prevalence of symptoms among patients with advanced cancer: an international collaborative study. symptom prevalence group. *J. Pain Symptom. Manage.* **12**: 3–10.
45. Smith, T.J. *et al.* 2002. Randomized clinical trial of an implantable drug delivery system compared with comprehensive medical management for refractory cancer pain: impact on pain, drug-related toxicity, and survival. *J. Clin. Oncol.* **20**: 4040–4049.
46. Krames, E.S. 1996. Intraspinal opioid therapy for chronic nonmalignant pain: current practice and clinical guidelines. *J. Pain Symptom. Manage.* **11**: 333–352.
47. Hassenbusch, S.J. *et al.* 2004. Polyanalgesic Consensus Conference 2003: an update on the management of pain by intraspinal drug delivery—report of an expert panel. *J. Pain Symptom. Manage.* **27**: 540–563.
48. Eisenach, J.C. *et al.* 1995. Epidural clonidine analgesia for intractable cancer pain. The epidural clonidine study group. *Pain* **61**: 391–399.
49. Coombs, D., L.H. Maurer, R.I. Saunders & M. Gaylor. 1984. Outcomes and complications of continuous intraspinal narcotic analgesia for cancer pain control. *J. Clin. Oncol.* **2**: 1414–1420.
50. Ackerman, L.L., K.A. Follett & R.W. Rosenquist. 2003. Long-term outcomes during treatment of chronic pain with intrathecal clonidine or clonidine/opioid combinations. *J. Pain Symptom. Manage.* **26**: 668–677.
51. Stearns, L. *et al.* 2005. Intrathecal drug delivery for the management of cancer pain: a multidisciplinary consensus of best clinical practices. *J. Support. Oncol.* **3**: 399–408.
52. Sjoberg, M. *et al.* 1994. Long-term intrathecal morphine and bupivacaine in patients with refractory cancer pain. Results from a morphine:bupivacaine dose regimen of 0.5:4.75 mg/ml. *Anesthesiology* **80**: 284–297.
53. Staats, P.S. *et al.* 2004. Intrathecal ziconotide in the treatment of refractory pain in patients with cancer or AIDS: a randomized controlled trial. *JAMA* **291**: 63–70.
54. Deer, T.K., E.S. Hassenbusch, *et al.* 2007. Polyanalgesic consensus conference 2007: recommendations for the management of pain by intrathecal (intraspinal) drug delivery: report of an interdisciplinary expert panel. *Neuromodulation* **10**: 301–328.
55. Elan Pharmaceuticals, I. 2005. Prialt (Ziconotide) Prescribing Information. Dublin.
56. Ridgeway, B., M. Wallace & A. Gerayli. 2000. Ziconotide for the treatment of severe spasticity after spinal cord injury. *Pain* **85**: 287–289.
57. Turner, J.A., J.M. Sears & J.D. Loeser. 2007. Programmable intrathecal opioid delivery systems for chronic noncancer pain: a systematic review of effectiveness and complications. *Clin. J. Pain.* **23**: 180–195.
58. de Lissovoy, G. *et al.* 1997. Cost-effectiveness of long-term intrathecal morphine therapy for pain associated with failed back surgery syndrome. *Clin. Ther.* **19**: 96–112; discussion 84–85.
59. Prager, J. & M. Jacobs. 2001. Evaluation of patients for implantable pain modalities: medical and behavioral assessment. *Clin. J. Pain* **17**: 206–214.

60. Hassenbusch, S.J. *et al.* 1995. Long-term intraspinal infusions of opioids in the treatment of neuropathic pain. *J. Pain. Symptom. Manage.* **10**: 527–543.
61. Devulder, J. *et al.* 1994. Spinal analgesia in terminal care: risk versus benefit. *J. Pain Symptom. Manage.* **9**: 75–81.
62. Onofrio, B.M. & T.L. Yaksh. 1990. Long-term pain relief produced by intrathecal morphine infusion in 53 patients. *J. Neurosurg.* **72**: 200–209.
63. Penn, R.D. & J.A. Paice. 1987. Chronic intrathecal morphine for intractable pain. *J. Neurosurg.* **67**: 182–186.
64. Meenan, D. *et al.* 1999. Managing intractable pain with an intrathecal catheter and injection port: technique and guidelines. *Am. Surg.* **65**: 1054–1060.
65. Ricci, V., A. Dalpane & E. Lolli. 1995. Continuous spinal analgesia in home care of oncologic pain. *Minerva. Med.* **86**: 409–414.
66. Schultheiss, R., J. Schramm & J. Neidhardt. 1992. Dose changes in long- and medium-term intrathecal morphine therapy of cancer pain. *Neurosurgery* **31**: 664–669; discussion 669–670.
67. Serlin, R.C. *et al.* 1995. When is cancer pain mild, moderate or severe? Grading pain severity by its interference with function. *Pain* **61**: 277–284.
68. Chochinov, H.M. *et al.* 1999. Will to live in the terminally ill. *Lancet* **354**: 816–819.
69. Lillemoe, K.D. *et al.* 1993. Chemical splanchnicectomy in patients with unresectable pancreatic cancer. A prospective randomized trial. *Ann. Surg.* **217**: 447–455; discussion 456–457.
70. Candido, K. & R.A. Stevens. 2003. Intrathecal neurolytic blocks for the relief of cancer pain. *Best. Pract. Res. Clin. Anaesthesiol.* **17**: 407–428.
71. Patt, R.B. 1993. *Cancer Pain*. Lippincott, Philadelphia, xxi, 650 p.
72. Cousins, M., B. Dwyer & D. Bigg. 1988. Chronic pain and neurolytic blockade. In *Neural Blockade in Clinical Anesthesia and Management of Pain*, 2 edn. M. Cousins & P.O. Bridenbaugh, Eds. JB Lippincott, Philadelphia.
73. Waxman, S. 2003. *Clinical Neuroanatomy*. Lange Medical Books/McGraw-Hill, New York.
74. Winnie, A. 1996. Subarachnoid neurolytic blocks. In *Interventional Pain Management*. W.A. Waldman, Ed., 401. WB Saunders, Philadelphia.
75. Gerbershagen, H.U. 1981. Neurolysis. Subarachnoid neurolytic blockade. *Acta Anaesthesiol. Belg.* **32**: 45–57.
76. Bonica, J.B., F.P., G. Moricca, *et al.* 1990. Neurolytic blockade and hypophysectomy. In *The Management of Pain*, 2nd edn. J. Bonica, Ed. Lea & Febiger, Philadelphia, 1980.
77. Kappis, M. 1919. Sensibilitat und lokale anasthesie im chirurgischen gebiet der bauchkikle mit besonderer berucksichtigung der splanchnicusanasthesia. *Beitr. Klin. Chir.* **115**: 161–175.
78. Ischia, S. *et al.* 1998 Labat Lecture: the role of the neurolytic celiac plexus block in pancreatic cancer pain management: do we have the answers? *Reg. Anesth. Pain. Med.* **23**: 611–614.
79. Eisenberg, E., D.B. Carr & T.C. Chalmers. 1995. Neurolytic celiac plexus block for treatment of cancer pain: a meta-analysis. *Anesth. Analg.* **80**: 290–295.
80. Ischia, S. *et al.* 2000. Celiac block for the treatment of pancreatic pain. *Curr. Rev. Pain.* **4**: 127–133.
81. Ward, E.M. *et al.* 1979. The celiac ganglia in man: normal anatomic variations. *Anesth. Analg.* **58**: 461–465.
82. Singler, R.C. 1982. An improved technique for alcohol neurolysis of the celiac plexus. *Anesthesiology* **56**: 137–141.
83. Woodburne, R. 1973. *Essentials of Human Anatomy*, 5th edn. 450–454. Oxford University Press, Oxford, England.
84. Boas, R. 1978. Sympathetic blocks in clinical practice. *Int. Anesthesiol. Clin.* **16**: 149–182.
85. Moore, D. 1984. Intercostal nerve block and celiac plexus block for pain therapy. In *Advances in Pain Research and Therapy*, Vol. 7. C. Beneditti, *et al.*, Eds. 309–329. Raven Press, New York.
86. Mercadante, S. and F. Nicosia. 1998. Celiac plexus block: a reappraisal. *Reg. Anesth. Pain Med.* **23**: 37–48.
87. Moore, D.C., W.H. Bush & L.L. Burnett. 1981. Celiac plexus block: a roentgenographic, anatomic study of technique and spread of solution in patients and corpses. *Anesth. Analg.* **60**: 369–379.
88. Lieberman, R.P. & S.D. Waldman. 1990. Celiac plexus neurolysis with the modified transaortic approach. *Radiology* **175**: 274–276.
89. Brown, D.L. & D.C. Moore. 1988. The use of neurolytic celiac plexus block for pancreatic cancer: anatomy and technique. *J. Pain Symptom. Manage.* **3**: 206–209.
90. Rathmell, J.P. 2006. *Atlas of Image-Guided Intervention in Regional Anesthesia and Pain Medicine*, 1st edn. 128–129. Lippincott Williams & Wilkins, Philadelphia.
91. Ischia, S. *et al.* 1983. A new approach to the neurolytic block of the coeliac plexus: the transaortic technique. *Pain* **16**: 333–341.
92. Romanelli, D.F., C.F. Beckmann & F.W. Heiss. 1993. Celiac plexus block: efficacy and safety of the anterior approach. *Am. J. Roentgenol.* **160**: 497–500.
93. Davies, D.D. 1993. Incidence of major complications of neurolytic coeliac plexus block. *J. R. Soc. Med.* **86**: 264–266.
94. Lieberman, R., S.L. Lieberman, D.J. Cuka & G.B. Lund. 1988. Celiac plexus and splanchnic nerve block: a review. *Semin. Intervent. Radiol.* **5**: 257–266.

95. Wong, G. & Brown, D.L. 1995. Transient paraplegia following alcohol celiac plexus block. *Reg. Anesth.* **20**: 352–355.
96. Woodham, M.J. & M.H. Hanna. 1989. Paraplegia after coeliac plexus block. *Anaesthesia* **44**: 487–489.
97. Prasanna, A. 1996. Unilateral celiac plexus block. *J. Pain Symptom Manage* **11**: 154–157.
98. Ischia, S.P. 1999. Computed tomography eliminates paraplegia and/or death from neurolytic celiac plexus block. *Reg. Anesthesia Pain Med.* **24**: 484–486.
99. Moore, D.C. 1999. Computed tomography eliminates paraplegia and/or death from neurolytic celiac plexus block. *Reg. Anesthesia Pain Med.* **24**: 483.
100. Mercadante, S. 1993. Celiac plexus block versus analgesics in pancreatic cancer pain. *Pain* **52**: 187–192.
101. Polati, E. *et al.* 1998. Prospective randomized double-blind trial of neurolytic coeliac plexus block in patients with pancreatic cancer. *Br. J. Surg.* **5**: 199–201.
102. Weber, J.G. *et al.* 1996. Celiac plexus block. Retrocrural computed tomographic anatomy in patients with and without pancreatic cancer. *Reg. Anesth.* **21**: 407–413.
103. Iki, K. *et al.* 2003. Celiac plexus block: evaluation of injectate spread by three-dimensional computed tomography. *Abdom. Imaging* **28**: 571–573.
104. Rosenberg, S.K. *et al.* 1998. Superior hypogastric plexus block successfully treats severe penile pain after transurethral resection of the prostate. *Reg. Anesth. Pain Med.* **23**: 618–620.
105. de Leon-Casasola, O.A. 2000. Critical evaluation of chemical neurolysis of the sympathetic axis for cancer pain. *Cancer Control.* **7**: 142–148.
106. Mauroy, B. *et al.* 2003. The inferior hypogastric plexus (pelvic plexus): its importance in neural preservation techniques. *Surg. Radiol. Anat.* **25**: 6–15.
107. Plancarte, R. *et al.* 1990. Superior hypogastric plexus block for pelvic cancer pain. *Anesthesiology* **73**: 236–239.
108. de Leon-Casasola, O.A., E. Kent & M.J. Lema. 1993. Neurolytic superior hypogastric plexus block for chronic pelvic pain associated with cancer. *Pain* **54**: 145–151.
109. Wechsler, R.J. *et al.* 1995. Superior hypogastric plexus block for chronic pelvic pain in the presence of endometriosis: CT techniques and results. *Radiology* **196**: 103–106.
110. Cariati, M. *et al.* 2002. CT-guided superior hypogastric plexus block. *J. Comput. Assist. Tomogr.* **26**: 428–431.
111. Michalek, P. & J. Dutka. 2005. Computed tomography-guided anterior approach to the superior hypogastric plexus for noncancer pelvic pain: a report of two cases. *Clin. J. Pain.* **21**: 553–556.
112. de Oliveira, R., M.P. dos Reis & W.A. Prado. 2004. The effects of early or late neurolytic sympathetic plexus block on the management of abdominal or pelvic cancer pain. *Pain* **110**: 400–408.
113. Kitoh, T. *et al.* 2005. Combined neurolytic block of celiac, inferior mesenteric, and superior hypogastric plexuses for incapacitating abdominal and/or pelvic cancer pain. *J. Anesth.* **19**: 328–332.
114. Waldman, S.D., W.L. Wilson & R.D. Kreps. 1991. Superior hypogastric plexus block using a single needle and computed tomography guidance: description of a modified technique. *Reg. Anesth.* **16**: 286–287.
115. Erdine, S. *et al.* 2003. Transdiscal approach for hypogastric plexus block. *Reg. Anesth. Pain Med.* **28**: 304–308.
116. Kanazi, G.E. *et al.* 1999. New technique for superior hypogastric plexus block. *Reg. Anesth. Pain Med.* **24**: 473–476.
117. Soysal, M.E. *et al.* 2003. Laparoscopic presacral neurolysis for endometriosis-related pelvic pain. *Hum. Reprod.* **18**: 588–592.
118. Chen, F.P., T.S. Lo & Y.K. Soong. 1998. Management of chylous ascites following laparoscopic presacral neurectomy. *Hum. Reprod.* **13**: 880–883.
119. Kwok, A., A. Lam & R. Ford. 2001. Laparoscopic presacral neurectomy: a review. *Obstet. Gynecol. Surv.* **56**: 99–104.
120. Plancarte, R. *et al.* 1997. Neurolytic superior hypogastric plexus block for chronic pelvic pain associated with cancer. *Reg. Anesth.* **22**: 562–568.
121. Chan, W.S. *et al.* 1997. Computed tomography scan-guided neurolytic superior hypogastric block complicated by somatic nerve damage in a severely kyphoscoliotic patient. *Anesthesiology* **86**: 1429–1430.
122. Dutka, J.M. 2002. Neurological complications in neurolytic blocks in the visceral and pelvic regions. *Int. Monitor. Reg. Anesth.* **14**: 69.
123. Plancarte, R.A., R.B. Patt, *et al.* 1990. Presacral blockade of the ganglion of Walther (ganglion impar). *Anesthesiology* **73**: A751.
124. Foye, P.M. 2007. New approaches to ganglion impar blocks via coccygeal joints. *Reg. Anesthesia Pain Med.* **32**: 269.
125. Hong, J.H. & H.S. Jang. 2006. Block of the ganglion impar using a coccygeal joint approach. *Reg. Anesthesia Pain Med.* **31**: 583.
126. Munir, M.A., J. Zhang & M. Ahmad. 2004. A modified needle-inside-needle technique for the ganglion impar block: [Une technique modifiée pour le bloc du ganglion coccygien : une aiguille dans une aiguille]. *Can. J. Anesth.* **51**: 915–917.
127. Nebab, E.G. & I.M. Florence. 1997. An alternative needle geometry for interruption of the ganglion impar. *Anesthesiology* **86**: 1213–1214.

128. Loev, M.A. *et al.* 1998. Cryoablation: a novel approach to neurolysis of the ganglion impar. *Anesthesiology* **88**: 1391–1393.
129. Yeo, S.N. & J.L. Chong. 2001. A case report on the treatment of intractable anal pain from metastatic carcinoma of the cervix. *Ann. Acad. Med. Singapore* **30**: 632–635.
130. Oh, C.S. *et al.* 2004. Clinical implications of topographic anatomy on the ganglion impar. *Anesthesiology* **101**: 249–250.
131. Reig, E. *et al.* 2005. Thermocoagulation of the ganglion impar or ganglion of walther: description of a modified approach. Preliminary results in chronic, nononcological pain. *Pain Practice* **5**: 103–110.
132. de Leon-Casasola, O. 1997. Superior hypogastric plexus block and ganglion impar neurolysis for pain associated with cancer. *Tech. Reg. Anesth Pain Manag.* **1**: 27–31.
133. Wemm, K., Jr. & L. Saberski. 1995. Modified approach to block the ganglion impar (ganglion of Walther). *Reg. Anesth.* **20**: 544–545.
134. Huang, J.J. 2003. Another modified approach to the ganglion of Walther block (ganglion of impar). *J. Clin. Anesth.* **15**: 282–283.
135. de Leon-Casaola, O.A. 2001. Ganglion impar block: critical evaluation. *Tech. Reg. Anesth. Pain Manag.* **5**: 120–122.
136. Swofford, J.R. & D.M. Ratzman. 1998. A transarticular approach to blockade of the ganglion impar (ganglion of walther). *Reg. Anesth. Pain. Med.* **23**: 103.